DOI: 10.3171/2014.7.SPINE131146

First report of major vascular injury due to lateral transpsoas approach leading to fatality

Case report

Rachid Assina, R.Ph., M.D., Neil J. Majmundar, B.S., Yehuda Herschman, M.D., and Robert F. Heary, M.D.

Department of Neurological Surgery, Rutgers University–New Jersey Medical School, Newark, New Jersey

Extreme lateral interbody fusion (XLIF) has gained popularity among spine surgeons for treating multiple conditions of the lumbar spine. In contrast to the anterior lumbar interbody fusion (ALIF) approach, the minimally invasive XLIF approach affords wide access to the lumbar disc space without an access surgeon and causes minimal tissue disruption. The XLIF approach offers many advantages over other lumbar spine approaches, with a reportedly low complication profile. The authors describe the first fatality reported in the literature following an XLIF approach. They describe the case of a 50-year-old woman who suffered a fatal intraoperative injury to the great vessels during a lateral transpsoas approach to the L4–5 disc space.
(http://thejns.org/doi/abs/10.3171/2014.7.SPINE131146)

Key Words • **extreme lateral interbody fusion** • **lateral transpsoas approach** • **complication** • **vascular injury** • **lumbar spine**

The minimally invasive lateral transpsoas approach is a modification of the open lateral retroperitoneal approach that was introduced by Pimenta in 2001 (Pimenta L, presented at the VIII Brazilian Spine Society Meeting). In 2006, Ozgur et al. described using a tubular dilator retractor system as the extreme lateral interbody fusion (XLIF) approach for the treatment of degenerative lumbar disease as an alternative to the anterior intraabdominal approaches.[13] In addition to its minimal tissue disruption, this procedure has been popularized among spine surgeons for its ability to allow direct wide access to the disc space without the need for an approach surgeon. In addition, mobilization of the great vessels is not necessary, which is perceived as a major benefit for this procedure.

We report the first intraoperative injury of the great vessels through the minimally invasive transpsoas approach, which ultimately resulted in a fatal outcome. We describe how to evaluate the patient preoperatively and how to select the ideal patient for this procedure to minimize and avoid the risk of an intraoperative vascular injury. We also assess the feasibility of this minimally invasive but potentially dangerous approach in an ambulatory surgicenter setting that typically lacks access to a vascular or a general surgeon.

Abbreviations used in this paper: ALIF = anterior lumbar interbody fusion; ALL = anterior longitudinal ligament; AP = anteroposterior; IVC = inferior vena cava; VB = vertebral body; XLIF = extreme lateral interbody fusion.

Case Report

History. The patient was a 50-year-old obese woman with a medical history significant for hypertension, coronary artery disease, peripheral vascular disease, hypercholesterolemia, and depression. She had previously undergone coronary artery bypass grafting of 3 vessels. The patient was transferred to our institution emergently from an ambulatory care surgicenter for a massive, exsanguinating, retroperitoneal hemorrhage. The blood loss occurred while she was undergoing a right-sided L4–5 XLIF procedure in which a tubular retractor system was used for the treatment of an L4–5 degenerated disc. The surgeon stated that he was able to identify and access the L4–5 level without any difficulty. He stated that the placement of the retractor was uneventful, but during the procedure the surgeon noticed that the anterior detachable blade (Scoville type retractor; Fig. 1) that is used to visualize the anterior longitudinal ligament (ALL) had

This article contains some figures that are displayed in color online but in black-and-white in the print edition.

advanced ventral to the L4–5 disc space. When he attempted to retract the detachable blade, he encountered tremendous bleeding. He packed the wound and was able to temporize the bleeding. When he attempted to manipulate the retractor a second time, extremely brisk venous bleeding was again encountered; therefore, he packed the retractor tube again and prepared to transport the patient to our facility. The patient was maintained in the left lateral decubitus position with the retractor in place and the wound packed. He transferred her emergently to our institution for exploration and treatment. Prior to transfer a call was placed from the surgicenter to our surgical team to alert the surgeons that an emergency situation was in progress.

Examination. After an initial assessment in the trauma bay, the operating surgeon informed our surgical team that any change in the patient's positioning would cause the retractor to move, resulting in potentially massive bleeding. Thus, the patient was kept immobilized in the left lateral decubitus position and transferred directly to the operating room where the vascular, cardiac, and neurosurgery teams were waiting. The right side of the patient's abdomen, flank, and groin as well as the retractor system were prepared and draped.

Emergency Operation. A percutaneous right femoral venogram demonstrated occlusion of the right common iliac vein just after the confluence of the external and internal iliac veins, with a large amount of extravasation of dye and an absence of dye in the inferior vena cava (IVC) (Fig. 2). After balloon occlusion proximal to the extravasation was achieved, the retroperitoneal space was accessed through a separate incision in the right lower quadrant where a large hematoma was observed along with a large clot in the IVC, which was clamped to prevent pulmonary emboli. The retractor was noted to be anterior to the ALL. The retractor tip had transected the right common iliac vein and was within the lumen of the left common iliac vein.

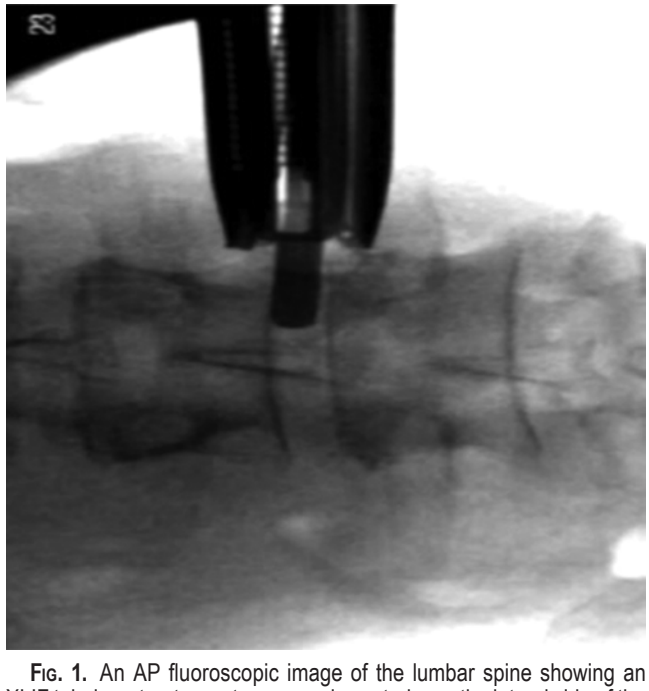

Fig. 1. An AP fluoroscopic image of the lumbar spine showing an XLIF tubular retractor system properly seated over the lateral side of the intervertebral disc space. The anterior detachable blade (Scoville type retractor) is appropriately placed in front of the ALL.

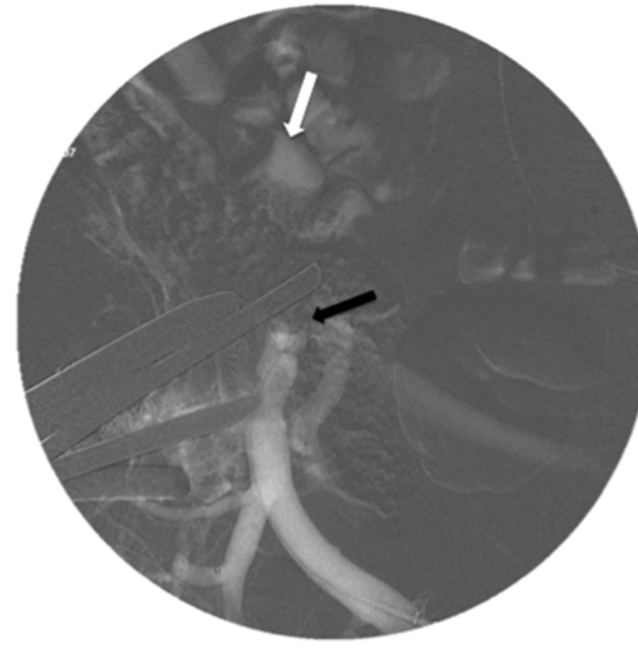

Fig. 2. Intraoperative percutaneous right femoral vein access venogram demonstrating occlusion of the right common iliac vein just after the confluence of the external and internal iliac veins *(black arrow)*, with large extravasation of contrast and absence of dye in the IVC *(white arrow)*.

Massive blood loss requiring transfusions of 29 units of packed red blood cells occurred. Ultimately, proximal and distal control was achieved. Once the retractors were removed, it was noted that there were many areas of perforation along the distal IVC, notably a 2-cm venotomy in its posterolateral aspect. There was a significant portion of the right common iliac vein missing as well as a large defect in the proximal left common iliac vein. After further exploration, it was noted that the right internal and external iliac veins were also injured. The IVC and the left common iliac defects were able to be repaired, but the right iliac venous drainage could not be salvaged due to the extensive damage caused by the detachable retractor blade.

Ultimately, hemostasis was successfully obtained and venous blood flow was restored through the left iliac venous system. Throughout the course of the procedure, the patient became hypotensive multiple times and digital pressure had to be applied so that the anesthesia service could keep up with the massive blood transfusion protocol. After receiving 29 units of packed red blood cells, 7300 ml of crystalloid fluids, and 3250 units of albumin for an estimated blood loss of 9200 ml, a consensus decision was made to keep the abdomen open and apply a negative-pressure wound vacuum. The patient also underwent bilateral lower-extremity full compartment fasciotomies. Intubation was left in place, and she was transferred to the surgical ICU in critical condition.

Postoperative Course. Over the course of the next 4 weeks, the patient returned to the operating room 5 times. She was eventually discharged to an acute care rehabilitation facility; however, she returned after 7 days with a retroperitoneal abscess and bacteremia. She became increasingly hemodynamically unstable over the next few days, and she died as a result of multiple organ failure secondary to septic shock.

Discussion

The lateral transpsoas minimally invasive approach was originally introduced as a novel surgical access technique to the anterior lumbar disc space for the treatment of patients with lumbar degenerative disc disease and axial low-back pain.[13] Advantages of the lateral approach are avoidance of the need for a vascular or a general access surgeon and the theoretically diminished likelihood of the potential morbidities of the anterior open intraabdominal approach. Besides minimal tissue disruption, this approach offers many other advantages such as minimal blood loss, early mobilization, decreased operating time, generous discectomy, reduced postoperative pain, and shorter hospital stays.[6,7,12,13,17] Because of these advantages, the application of this approach has been stretched to its broadest possible use from its original indication[13] to treat a variety of thoracolumbar spinal disorders.[1] Despite this wide practice, we reserve this approach for the ideal indications to obtain optimal results. Patients who would be considered for an anterior lumbar interbody fusion (ALIF) are good candidates for this approach, especially if they are obese or concerned about postoperative sexual function. Patients with central canal stenosis, spondylolisthesis greater than Grade I, and scoliotic deformity with axial rotation are not considered candidates for the procedure.

Some of the most common complications associated with a traditional open ALIF approach are vascular injury, postsympathectomy syndrome, and retrograde ejaculation.[2,5,8,9,14,19] There is a high incidence, between 2% and 15%, of vascular injury with this approach secondary to the mobilization of the great vessels, especially the iliac veins.[2,4,19,21] The XLIF was introduced as an approach to bypass the need for the manipulation of the great vessels and consequently to decrease the likelihood of their injury. This belief is reinforced and demonstrated by the lack of reporting of this type of injury in the literature. Santillan et al. reported a vascular injury of the left L-2 segmental artery after an L2–3 XLIF procedure that was thought to be caused by the lateral expandable split retractor blade.[18] The injury was discovered 48 hours postoperatively when the patient became hemodynamically unstable and a CT scan showed a large left retroperitoneal hematoma. Immediately, the patient underwent a successful endovascular embolization of a left L-2 segmental artery pseudoaneurysm.

Hu et al. performed an MRI study of the great vessels with respect to the lateral transpsoas approach in 48 individuals with nondeformed lumbar spine and learned that the vena cava migrates from Zone A to Zone 1, while descending from L-1 to L-5 (Fig. 3).[10] They divided the vertebral body (VB) according to the method of Moro et al.[11] into 6 zones and discovered that the vena cava at the L4–5 level was located at the right of Zone 1 in 29.2% of the subjects, and at the right junction of Zones 1 and A in 52%.[10] This study suggests that in 70.8% of the subjects the vena cava would be at risk for injury if the lumbar spine is accessed using the right lateral transpsoas approach, making the approach theoretically safer from the left in regard to the possibility of injuring the vena cava. The aorta was found to be at the left Zone A in 29.2% of the subjects, making it vulnerable if the lumbar spine is accessed using the left lateral transpsoas approach. The risk of injuring the great vessels is much higher in patients with degenerative scoliosis, in whom axial rotation shifts these vessels to a more posterior position in the concave side of the deformity.[15]

The lateral transpsoas approach uses a corridor that was designed to have a maximum intervertebral space exposure, with avoidance of the anterior and posterior vital structures; however, this corridor gets considerably narrower from the L1–2 level down to the L4–5 level. It gets narrower both anteriorly as the great vessels move more posteriorly and laterally toward the anterior surface of the VBs, and also posteriorly as the neural elements move anteriorly on the lateral surface of the VBs.[15] To decrease the potential for neural damage, it has been recommended that the surgeon perform the dissection in the anterior two-thirds of the disc space,[5,20] especially at the L4–5 disc space level where the large vessels are more ventrally located,[3] putting them at a greater risk of injury. Both Moro et al. and Hu et al. describe Zone 1 as one-fourth of the lateral VB, as the only safe corridor at the L4–5 level for a right lateral transpsoas approach.[10,11] They defined Zones 2 and 3, one-half of the lateral VB, as the safest corridor for this level if approached from the left. Although it is safer to access the L4–5 level using the left lateral transpsoas approach at Zones 2 and 3, failure to recognize the oval shape of the VB in the axial plane may lead to the rectangular-shaped graft injuring the great vessels on the right side, because the contralateral anulus is routinely released as part of the procedure. The risk is much greater in degenerative scoliosis with axial rotation.[16]

In our case, in addition to operating at the level with the narrowest working channel (L4–5), the surgeon used a detachable, nonfixed anterior blade (Fig. 1) that slipped anteriorly, injuring the posterior wall of the IVC and the right iliac vein confluence (Fig. 2). Because there was no vascular or general surgeon available in the outpatient surgicenter, the operating surgeon appropriately elected to transport this unstable patient to our institution. He was obliged to leave the retractor in place, including the misplaced loose anterior blade, in addition to multiple sterile packs, because every time he attempted to move either the retractor or the packing an overwhelming blood loss was encountered. It is likely that the vascular injury became progressively worse during transportation to our facility; there were multiple vessel injuries at the time of exploration in the operating room. These were at 5 distinct locations: the distal posterior IVC, the right common iliac vein, the right internal iliac vein, the right external

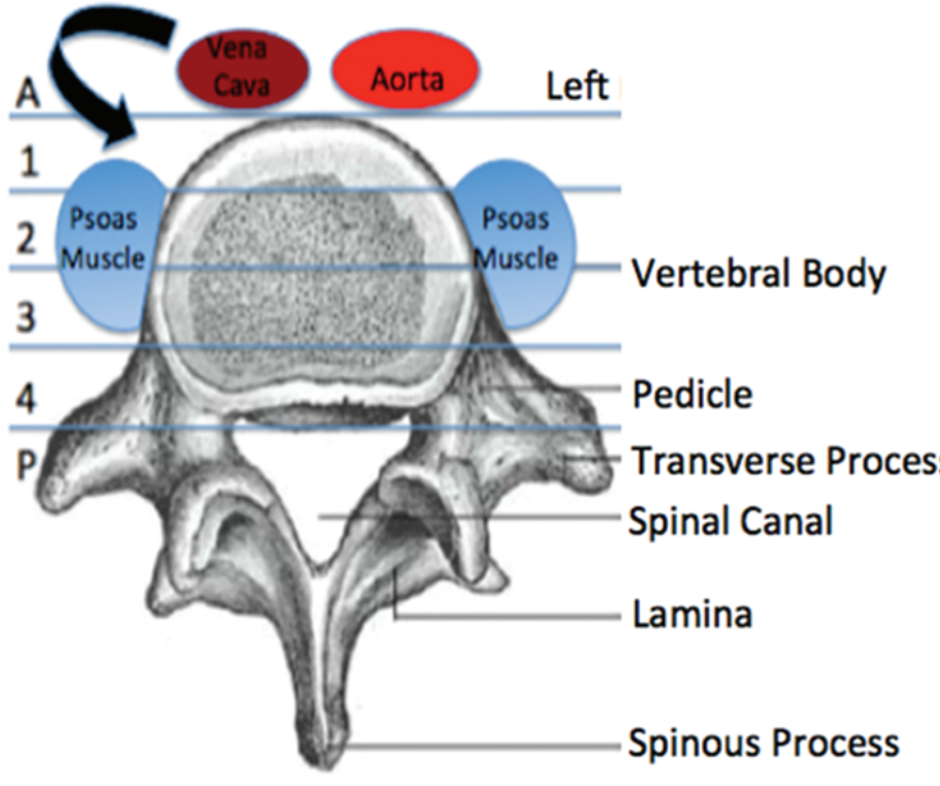

Fig. 3. Schematic showing a lumbar VB, which is divided into 6 zones according to the Moro system. Zone A defines the most anterior aspect and Zone P the most posterior aspect of the VB. The vena cava migrates posteriorly and laterally *(arrow)* as it travels from L-1 to L-5.

iliac vein, and the left common iliac vein. The unsecured, loose retractor blade continued to damage the fragile walls of these large venous structures during transport to our facility, despite the surgeon's attempts to secure it (Fig. 4).

The success of any surgical procedure depends primarily on the selection of the right patient for the right indication (Table 1). Patients who would be considered for an ALIF are good candidates for this approach, especially if they are obese, have a history of prior abdominal surgery, or are concerned with sexual function. Patients with central canal stenosis, spondylolisthesis greater than Grade I, and scoliotic deformity with axial rotation are not considered candidates for the procedure. In addition to an MRI sequence, we routinely obtain a preoperative lumbar spine CT scan to assess the vascular anatomy in relation to the ALL and the VB to determine the safest side from which to perform the lateral approach. The ideal side should be where the great vessels are traveling more anteriorly and medially in relation to the anterior surface of the intended interbody level. We obtain anteroposterior (AP), lateral, and bending plain radiographs to assess the obstruction of the iliac crest for access to the lumbar spine. Because L4–5 is the level that is the most difficult to gain access to, and the most vulnerable level for vascular and neural injury, we recommend hesitancy when considering this procedure at this level.

In the operating room, care is taken to tape the patient securely to the operating table, which would be adjusted to obtain the perfect AP and lateral films. Intraoperative

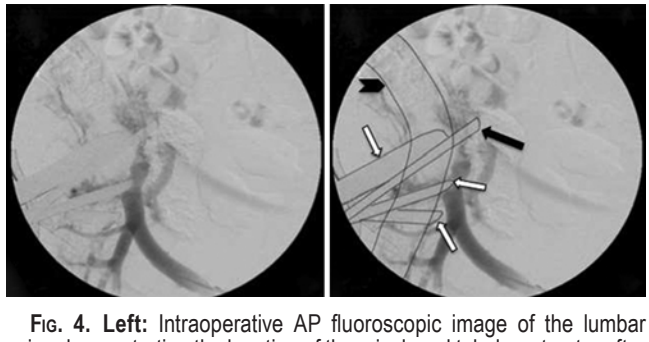

Fig. 4. Left: Intraoperative AP fluoroscopic image of the lumbar spine demonstrating the location of the misplaced tubular retractor after transportation of the patient to our institution. **Right:** The tubular retractor is splayed open with the blades anteriorly located *(white arrows)* instead of being positioned on the lateral side of the VBs *(arrowhead)*. The anterior detachable blade (Scoville type retractor; *black arrow*) is completely plunged into the retroperitoneal space, severing the IVC and both common iliac veins.

TABLE 1: Generally accepted indications for lateral transpsoas approach for L1–L5 interbody fusion

1. degenerative disc disease w/ instability &/or foraminal stenosis
2. degenerative spondylolisthesis Grade I
3. degenerative lumbar scoliosis w/ < Grade II axial rotation & no lateral listhesis
4. adjacent-level disease
5. posterior pseudarthrosis

neurological monitoring is done throughout the case to assist in finding and maintaining the safest corridor. Only one lateral incision is made and the psoas muscle is exposed under direct visualization. The tubular system is used without the detachable blade, and care is taken not to violate the ALL. We recommend that instruments with an open mouth, such as the pituitary forceps or the Kerrison rongeurs, be open facing posteriorly so that they will not violate the ALL and accidently capture the great vessels anteriorly. We try to minimize the time of retractor use to decrease the likelihood of compression injury to the lumbar plexus. To avoid abdominal hernias, all the layers are approximated with Vicryl sutures. If we are unable to get a good closure at the level of the transversalis fascia, we use a hernia surgical mesh to repair the defect.

As this approach gains more popularity and wider usage among experienced and nonexperienced spine surgeons, the real potential for injury to the great vessels must be recognized. This possibility is particularly worrisome if a tubular retractor system that has a detachable, nonfixed retractor blade anteriorly is used. A thorough understanding of the vascular anatomy in relation to the ALL is necessary, because a vascular injury is possible anytime the ALL is violated. This report also demonstrates the danger of performing an XLIF surgical procedure in an outpatient surgicenter without immediate access to a vascular, endovascular, or general surgery back-up practitioner.

Disclosure

The authors report no conflict of interest concerning the materials or methods used in this study or the findings specified in this paper.

Author contributions to the study and manuscript preparation include the following. Conception and design: Heary, Assina. Acquisition of data: all authors. Analysis and interpretation of data: Heary, Assina, Majmundar. Drafting the article: all authors. Critically revising the article: all authors. Reviewed submitted version of manuscript: all authors. Approved the final version of the manuscript on behalf of all authors: Heary. Statistical analysis: Assina, Herschman. Administrative/technical/material support: Heary, Assina. Study supervision: Heary, Assina, Herschman.

References

1. Arnold PM, Anderson KK, McGuire RA Jr: The lateral transpsoas approach to the lumbar and thoracic spine: a review. **Surg Neurol Int 3 (Suppl 3):**S198–S215, 2012
2. Baker JK, Reardon PR, Reardon MJ, Heggeness MH: Vascular injury in anterior lumbar surgery. **Spine (Phila Pa 1976) 18:**2227–2230, 1993
3. Benglis DM, Vanni S, Levi AD: An anatomical study of the lumbosacral plexus as related to the minimally invasive transpsoas approach to the lumbar spine. Laboratory investigation. **J Neurosurg Spine 10:**139–144, 2009
4. Brau SA: Mini-open approach to the spine for anterior lumbar interbody fusion: description of the procedure, results and complications. **Spine J 2:**216–223, 2002
5. Christensen FB, Bünger CE: Retrograde ejaculation after retroperitoneal lower lumbar interbody fusion. **Int Orthop 21:**176–180, 1997
6. Dakwar E, Cardona RF, Smith DA, Uribe JS: Early outcomes and safety of the minimally invasive, lateral retroperitoneal transpsoas approach for adult degenerative scoliosis. **Neurosurg Focus 28(3):**E8, 2010
7. Deluzio KJ, Lucio JC, Rodgers WB: Editorial. Value and cost in less invasive spinal fusion surgery: lessons from a community hospital. **SAS J 4:**37–40, 2010
8. Flynn JC, Price CT: Sexual complications of anterior fusion of the lumbar spine. **Spine (Phila Pa 1976) 9:**489–492, 1984
9. Hrabalek L, Adamus M, Gryga A, Wanek T, Tucek P: A comparison of complication rate between anterior and lateral approaches to the lumbar spine. **Biomed Pap Med Fac Univ Palacky Olomouc Czech Repub 158:**127–132, 2014
10. Hu WK, He SS, Zhang SC, Liu YB, Li M, Hou TS, et al: An MRI study of psoas major and abdominal large vessels with respect to the X/DLIF approach. **Eur Spine J 20:**557–562, 2011
11. Moro T, Kikuchi S, Konno S, Yaginuma H: An anatomic study of the lumbar plexus with respect to retroperitoneal endoscopic surgery. **Spine (Phila Pa 1976) 28:**423–428, 2003
12. Oliveira L, Marchi L, Coutinho E, Abdala N, Pimenta L: The use of rh-BMP2 in standalone eXtreme Lateral Interbody Fusion (XLIF®): clinical and radiological results after 24 months follow-up. **WScJ 1:**19–25, 2010
13. Ozgur BM, Aryan HE, Pimenta L, Taylor WR: Extreme Lateral Interbody Fusion (XLIF): a novel surgical technique for anterior lumbar interbody fusion. **Spine J 6:**435–443, 2006
14. Regan JJ, McAfee PC, Guyer RD, Aronoff RJ: Laparoscopic fusion of the lumbar spine in a multicenter series of the first 34 consecutive patients. **Surg Laparosc Endosc 6:**459–468, 1996
15. Regev GJ, Chen L, Dhawan M, Lee YP, Garfin SR, Kim CW: Morphometric analysis of the ventral nerve roots and retroperitoneal vessels with respect to the minimally invasive lateral approach in normal and deformed spines. **Spine (Phila Pa 1976) 34:**1330–1335, 2009
16. Regev GJ, Haloman S, Chen L, Dhawan M, Lee YP, Garfin SR, et al: Incidence and prevention of intervertebral cage overhang with minimally invasive lateral approach fusions. **Spine (Phila Pa 1976) 35:**1406–1411, 2010
17. Rodgers WB, Cox CS, Gerber EJ: Experience and early results with a minimally invasive technique for anterior column support through eXtreme Lateral Interbody Fusion: XLIF. **US Musculoskeletal Review 2:**28–32, 2007
18. Santillan A, Patsalides A, Gobin YP: Endovascular embolization of iatrogenic lumbar artery pseudoaneurysm following extreme lateral interbody fusion (XLIF). **Vasc Endovascular Surg 44:**601–603, 2010
19. Tiusanen H, Seitsalo S, Osterman K, Soini J: Anterior interbody lumbar fusion in severe low back pain. **Clin Orthop Relat Res (324):**153–163, 1996
20. Uribe JS, Arredondo N, Dakwar E, Vale FL: Defining the safe working zones using the minimally invasive lateral retroperitoneal transpsoas approach: an anatomical study. Laboratory investigation. **J Neurosurg Spine 13:**260–266, 2010
21. Westfall SH, Akbarnia BA, Merenda JT, Naunheim KS, Connors RH, Kaminski DL, et al: Exposure of the anterior spine. Technique, complications, and results in 85 patients. **Am J Surg 154:**700–704, 1987

Manuscript submitted December 19, 2013.
Accepted July 29, 2014.
Please include this information when citing this paper: published online September 5, 2014; DOI: 10.3171/2014.7.SPINE131146.
Address correspondence to: Robert F. Heary, M.D., Department of Neurological Surgery, 90 Bergen St., Ste. 8100, Newark, NJ 07103. email: heary@njms.rutgers.edu.