



Clinical Study

Minimally invasive lateral extracavitary resection of foraminal neurofibromas

Elias Dakwar^{a,*}, William D. Smith^b, Kyle T. Malone^c, Juan S. Uribe^a^a Department of Neurosurgery and Brain Repair, University of South Florida, 2 Tampa General Circle, 7th floor, Tampa, FL 33606, USA^b Western Regional Center for Brain and Spine Surgery, Las Vegas, NV, USA^c NNI Research Foundation, Las Vegas, NV, USA

ARTICLE INFO

Article history:

Received 3 February 2011

Accepted 2 April 2011

Keywords:

Dlif
 Extracavitary
 Lateral
 Minimally invasive
 Neurofibroma
 Xlif

ABSTRACT

Nerve sheath tumors are the most common spinal tumors but extradural foraminal nerve sheath tumors are much rarer. Traditionally, these nerve sheath tumors have been resected via an open posterior approach. We describe an alternative minimally invasive (MIS) lateral extracavitary approach for resection of symptomatic extradural foraminal spinal neurofibromas. We describe three consecutive male patients (mean age, 37 years) who underwent a successful MIS lateral extracavitary approach for surgical resection of symptomatic extradural spinal neurofibromas. All patients presented with pain and two of the three presented with neurological deficit. Follow-up data, including functional and radiographic outcomes, were collected for all patients. The mean operative time, blood loss, and length of stay were 85 minutes (min) (range, 60–120 min), 150 mL (range, 100–200 mL), and two days (range, 1–3 day), respectively. There were no complications. All patients had complete resolution of their pain and motor deficits. Thus, the MIS lateral extracavitary approach is a safe and feasible alternative for resection of spinal extradural foraminal neurofibromas.

© 2011 Elsevier Ltd. All rights reserved.

1. Introduction

Spinal neuromas, or nerve sheath tumors, are the most common spinal tumor, affecting men and women in equal proportions. Spinal neuromas and neurofibromas carry an excellent prognosis after complete removal. They may occur in any age group and affect patients between their 3rd and 7th decades in equal proportions.¹ They can be intradural, extradural, or both (dumbbell shape). Purely extradural neurofibromas of the thoracic or lumbar spine are very rare.^{2,3}

The surgical approach to these extradural foraminal nerve sheath tumors depends on the location and the extent of the lesion. Current approaches to lower thoracic nerve sheath tumors include thoracotomy, thoracoscopic, costotransversectomy, or a combination of these. Traditionally, foraminal tumors of the lumbar spine have been resected using a posterior or posterolateral approach to perform a laminectomy and a partial or complete facetectomy. This approach necessitates many of the patients to undergo instrumentation and fusion secondary to destabilization.

Recently, the minimally invasive (MIS) lateral extracavitary approach has been developed and avoids many of the disadvantages of the traditional approaches. This approach is increasingly being deployed to treat many spinal pathologies. We present our experience using this advanced application of the MIS lateral

approach for resection of extradural foraminal neurofibromas (EFN).

2. Methods and materials

Between 2008 and 2009, three consecutive patients presented with symptomatic EFN of the thoracic or lumbar spine. All patients underwent a MIS lateral extracavitary (retroperitoneal/retropleural) approach for resection of their tumors. All patients presented with pain and two of three (66%) presented with a neurological deficit. Preoperative evaluation consisted of a physical examination and radiological imaging, including MRI scans with gadolinium (Fig. 1). Preoperative and postoperative outcome questionnaires, including the visual analog scale (VAS) scores, were obtained. MRI was used to assess the extent of resection. Operative time, estimated blood loss (EBL), length of hospital stay, and complications were assessed.

2.1. Surgical technique

The modified surgical procedure, as previously described,⁴ consisted of patients being placed in the lateral decubitus position on a radiolucent table with fluoroscopic localization of the affected level. In all patients, the side of the approach was chosen according to the vertebral level and the location of the abnormality. Under fluoroscopic guidance, the index level and pathology were located and marked on the skin. A 4–6 cm incision was made, and depending on the location, either the retroperitoneal or retropleural

* Corresponding author. Tel.: +1 813 259 0821.

E-mail address: edakwar@health.usf.edu (E. Dakwar).

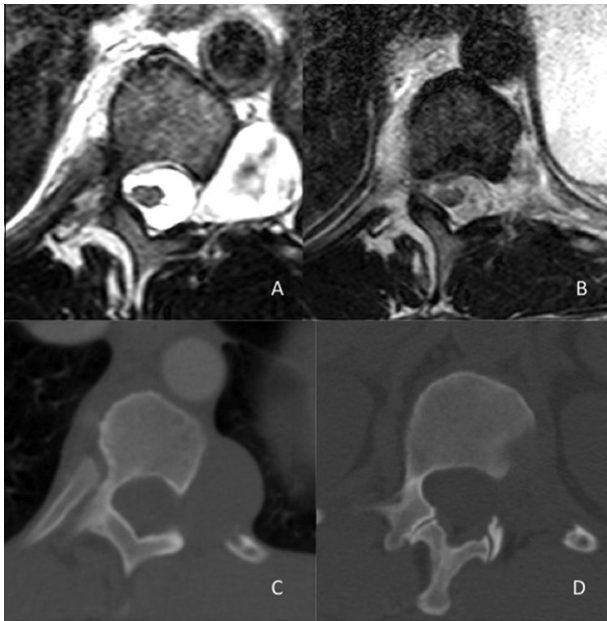


Fig. 1. (A) Preoperative and (B) postoperative axial MRI and (C) preoperative and (D) postoperative axial CT scans showing a T11/12 neurofibroma resected through the minimally invasive lateral retropleural approach.

(extracavitary) space was accessed using blunt dissection to expose the lateral surface of the spine. When a retropleural approach was needed, a 6-cm long oblique incision (following the trajectory of the rib at the index level) was made at the mid-axillary line. Approximately 5 cm of the rib immediately overlying the target level was dissected subperiosteally from the underlying pleura and neurovascular bundle and removed. Once the parietal pleura was exposed, the plane between the endothoracic fascia and the pleura was developed. The pleura was then mobilized anteriorly until the lateral surface of the spine was exposed. Once an arm-mounted expandable tube retractor (MaXcess, NuVasive, San Diego, CA, USA) had been placed, the neurofibromas were resected using the standard microsurgical technique. No bony or ligamentous structures of the spine were removed (Fig. 2).

3. Patients

3.1. Patient 1

A 48-year-old male with a past medical history significant for neurofibromatosis type 1, presented with progressive debilitating

pain in the left abdominal wall. The preoperative VAS pain score reported by the patient was 9/10. On examination he had pain and sensory loss in the left T11–12 distribution. No motor deficits or evidence of myelopathy were identified. MRI demonstrated an enhancing well-circumscribed mass measuring 3 cm by 3.1 cm located in the left T11/12 neuroforamen consistent with a neurofibroma (Fig. 1). The patient underwent a MIS lateral extracavitary approach and resection of the tumor. The patient had an uneventful postoperative course. The estimated blood loss was 150 mL and the operative time was 2 hours. There were no perioperative complications. At last follow-up, the patient had complete resolution of his radiculopathy. The postoperative pathology report confirmed the diagnosis of neurofibroma.

3.2. Patient 2

A 37-year-old male with no significant past medical history presented with a 1-year history of back pain with radiation towards the left groin. The preoperative VAS score reported by the patient was 9/10. On examination, the patient had decreased sensation in the left L1 distribution with trace weakness (4+/5) of left hip flexion. MRI revealed a 4 cm by 2.6 cm enhancing mass within the left neural foramen and extending laterally into the psoas muscle at the L1/2 level. The patient underwent a MIS lateral extracavitary approach and resection of the tumor. Total operative time was 60 min and the estimated blood loss was 200 mL. At 6-weeks postoperative follow-up, the patient had full recovery of motor strength with no muscle weakness, although muscle spasms persisted. Postoperative MRI at 9 months revealed resection of the left-sided foraminal mass with a small amount of residual nodular tissue within the left foramen measuring approximately 5 mm at the L1–2 level. The postoperative pathology report confirmed the diagnosis of neurofibroma.

3.3. Patient 3

A 26-year-old male with a past medical history of neurofibromatosis type 2 presented with a history of progressive back pain with radiation down the left leg. His preoperative VAS score reported by the patient was 8/10. On examination, the patient had decreased sensation in the left L3 dermatome and 3/5 weakness of left knee extension. MRI revealed a large 3.4 cm by 2.6 cm nerve sheath tumor growing through the left neural foramen and extending into the psoas muscle at the L3/4 level. The patient underwent a MIS lateral extracavitary approach and resection of the tumor (Fig. 2). Total operative time was 75 min and the estimated blood loss was 100 mL. At the 3-month follow-up, the patient had

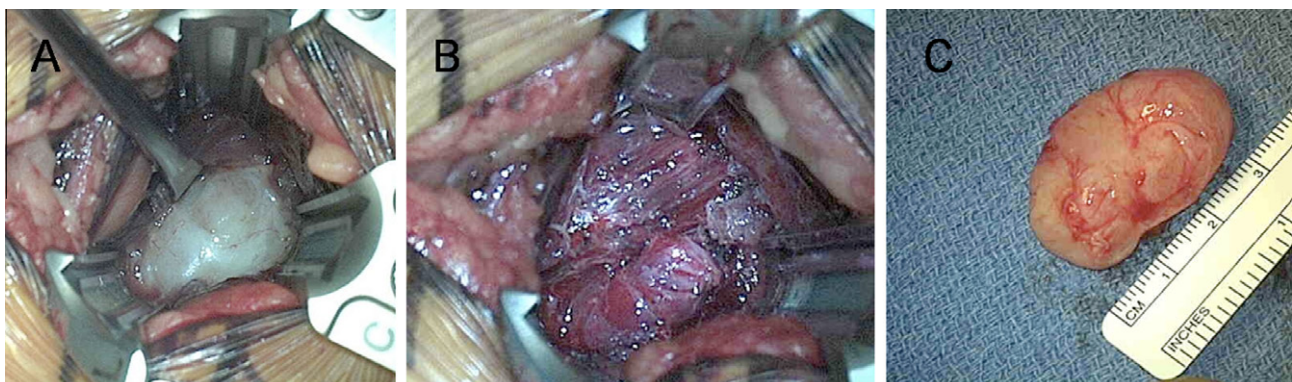

Fig. 2. Intraoperative photographs showing (A) the exposed L3 tumor, (B) status post resection, and (C) the resected tumor. (This figure is available in colour at www.sciencedirect.com.)

Table 1
Patients who underwent minimally invasive lateral extracavitary resection of extradural foraminal neurofibromas

Patient no.	Age/sex	Location	Size (cm)	Blood Loss (mL)	Operative time (min)	VAS (Pre/post)
1	48/M	T11/12	3 × 3.1	150	120	9/0
2	37/M	L1/2	4 × 2.6	200	60	9/0
3	26/M	L3/4	3.4 × 2.6	100	75	8/0

Min: minutes, M = male, pre = preoperative, post = postoperative. VAS = visual analogue scale.

complete recovery of motor strength and resolution of his pain. The postoperative pathology report confirmed the diagnosis of neurofibroma. Patient details have been summarized in Table 1.

4. Results

The three patients underwent successful resection of their neurofibromas using the MIS lateral extracavitary approach. The three patients were males with a mean age of 37 years (range, 26–48 years). The mean operative time was 85 min (range, 60–120 min), the mean EBL was 150 mL (range, 100–200 mL), and the mean length of hospital stay was 2 days (range, 1–3 days). Mean follow-up was 9 months with a range of 6 months to 12 months. There were no perioperative complications. No patient required a blood transfusion. There were no intraoperative cerebrospinal fluid (CSF) leaks, wound infections, or postoperative weaknesses identified. There were no injuries to the peritoneal or retroperitoneal structures. There were no deep venous thromboses, urinary tract infections, or ileus identified. There was no pneumothorax or pneumonia in the patients who underwent a retropleural approach. All patients had complete resolution of their pain and motor deficits at their last follow-up. Postoperative MRI demonstrated complete resection of the neurofibromas in two patients and tiny residual in the third patient. No bone or critical ligamentous structures were removed, and therefore there was no need for instrumentation. Postoperative upright radiographs were performed on all patients and showed no signs of instability.

5. Discussion

Nerve sheath tumors are the most common spinal tumors and make up almost one-third of primary spinal neoplasms.⁵ Clinically, patients present with signs and symptoms related to the spinal level involved and extent of tumor. Most patients present with pain and paresthesia, but motor deficits can also be seen.^{1,2} Neurofibromas can be intradural, extradural, or a combination of both.² Purely EFN that extend lateral to the facet are rare, especially in the lower thoracic and lumbar spine. Traditional resection of these tumors included a laminectomy and possible facetectomy. If a radical facetectomy was performed, then fusion was typically required.^{3,6}

Current open posterior approaches require aggressive muscle dissection from the underlying bony anatomy and removal of the lamina and facet joint to adequately visualize the lesion for resection. These procedures have been used to achieve good outcomes. However, with recent advances in MIS techniques, many surgeries are being performed with an emphasis on minimizing tissue disruption. Recently, Lu et al. described a mini-open removal of extradural foraminal tumors from a posterior approach with satisfactory results.⁷ However, this technique still required instrumentation

and fusion of the affected levels secondary to removal of the facet joint.

This current study describes our experience with the MIS lateral extracavitary approach for resection of extradural foraminal nerve sheath tumors. This technique allows access to the lateral surface of the vertebral body and neural foramen, especially lateral to the facet joint, with minimal muscle dissection and no bony removal. Since there is no facetectomy or destabilization, no fusion is required. Whether located in the thoracic or lumbar spine, extradural foraminal tumors can be accessed without violation of the pleural or peritoneal cavity. This approach provided adequate access, while avoiding many of the morbidities of the conventional approaches. Another advantage of this approach is the lack of need for an access surgeon.

The most important considerations in using this approach for nerve sheath tumors are the location and size of the lesion. Intradural tumors and tumors located medial to the facet with extensions into the spinal canal cannot be easily accessed with this approach. Tumors located below the L4/5 disc space are also not easily accessible secondary to the iliac crest. Since the resection is performed through an expandable retractor, the lesion should be less than the maximum expansion size of the retractor. As with all new techniques and MIS surgeries, this approach has a steep learning curve. Also, there is a limited surgical corridor inside the tube with a relatively long working distance.

6. Conclusions

Spinal extradural foraminal nerve sheath tumors can be safely resected using the MIS lateral extracavitary approach. This approach provides good access while minimizing tissue disruption. Degree of resection, blood loss, and operative time are acceptable using this technique. No paraspinous muscle dissection, bony removal, or fusion is necessary. This technique is a safe alternative to conventional procedures.

References

- Levy WJ, Latchaw J, Hahn JF, et al. Spinal neurofibromas: a report of 66 cases and a comparison with meningiomas. *Neurosurgery* 1986;**18**:331–4.
- Celli P, Trillo G, Ferrante L. Spinal extradural schwannoma. *J Neurosurg Spine* 2005;**2**:447–56.
- Jinnai T, Koyama T. Clinical characteristics of spinal nerve sheath tumors: analysis of 149 cases. *Neurosurgery* 2005;**56**:510–5.
- Ozgur BM, Aryan HE, Pimenta L, et al. Extreme Lateral Interbody Fusion (XLIF): a novel surgical technique for anterior lumbar interbody fusion. *Spine J* 2006;**6**:435–43.
- Nittner K. Diagnosis and treatment of intraspinal expansive processes. *Acta Neurol Psychiatr Belg* 1968;**68**:519–42.
- Ozawa H, Kokubun S, Aizawa T, et al. Spinal dumbbell tumors: an analysis of a series of 118 cases. *J Neurosurg Spine* 2007;**7**:587–93.
- Lu DC, Dhall SS, Mummaneni PV. Mini-open removal of extradural foraminal tumors of the lumbar spine. *J Neurosurg Spine* 2009;**10**:46–50.