

Technical nuances of the minimally invasive extreme lateral approach to treat thoracolumbar burst fractures

Gurpreet S. Gandhoke¹ · Zachary J. Tempel¹ · Christopher M. Bonfield¹ · Ricky Madhok² · David O. Okonkwo¹ · Adam S. Kanter¹

Received: 7 January 2015 / Revised: 25 February 2015 / Accepted: 11 March 2015
© Springer-Verlag Berlin Heidelberg 2015

Abstract

Purpose Contemporary minimally invasive techniques have evolved to enable direct access to the anterior spinal column via the extreme lateral approach. We have employed this access approach to treat selected burst fractures. We report our technique. Thoracolumbar burst fractures that require surgical intervention have traditionally been managed with anterior, posterior, or combined approaches. **Methods** We have applied the minimally invasive extreme lateral approach to perform vertebral corpectomy, cage placement, and lateral instrumentation to treat burst fractures. Indications for surgery were incomplete spinal cord injury with persistent neural element compression due to ventral fracture fragments in the canal. We present the technical nuances of this surgical approach for the treatment of thoracolumbar burst fractures with two case illustrations.

Results There were no peri- or intra-operative complications. Both patients in our series remained neurologically intact at their last follow-up (11 and 29 months, respectively), and maintained their correction of kyphosis.

Conclusion The minimally invasive extreme lateral approach is an effective treatment option for the management of thoracolumbar burst fractures.

Keywords Thoracolumbar burst fracture · Spine trauma · Extreme lateral approach · Minimally invasive spine surgery

Introduction

Indications for surgical management of acute thoracolumbar burst fractures are well described and include decompression of neural elements, restoration of spinal alignment, and promotion of arthrodesis [1–4]. Patients requiring surgery for thoracolumbar burst fractures may be treated via an anterior approach, posterior approach or combined anterior–posterior approach. The goals of surgery are neural decompression, stabilization and correction of an associated deformity when present. Anterior instrumentation has been shown to produce equivalent arthrodesis and correction of kyphotic deformity compared to posterior instrumentation, while allowing for direct visualization of the spinal canal and theoretically, a superior decompression [5]. However, traditional anterior approaches to the thoracolumbar spine carry significant morbidity, including pneumothorax, aortic injury, disruption of the lumbar plexus, retrograde ejaculation, and development of abdominal or diaphragmatic hernia [6].

To minimize exposure-related morbidity, a number of anterolateral laparoscopic and thoracoscopic approaches for instrumentation at the thoracolumbar junction have been attempted [7]. The minimally invasive extreme lateral approach is a technique that has been previously described for the treatment of spine pathology including degenerative and scoliotic lumbar disease [8]. Its use in trauma, particularly in the treatment of burst fractures, is more limited in the literature. We report an extrapolation of the contemporary minimally invasive extreme lateral approach to

✉ Zachary J. Tempel
tempelzj@upmc.edu

¹ Department of Neurological Surgery, University of Pittsburgh Medical Center, 200 Lothrop Street, Suite B-400, Pittsburgh, PA 15213, USA

² North Shore University Hospital, New York, NY, USA

enable anterior decompression and instrumented fusion of acute unstable thoracolumbar burst fractures.

Methods

We describe two patients who underwent an extreme lateral approach for the treatment of unstable L1 burst fractures. One patient underwent a posterior decompression and fusion followed by the extreme lateral access to reconstruct the anterior column. The second patient had an exclusive extreme lateral approach to treat his burst fracture. Both patients presented immediately following traumatic injury. Preoperative evaluation consisted of physical examination, computerized tomography (CT) of the thoracolumbar spine, and magnetic resonance imaging (MRI) of the thoracolumbar spine. American Spinal Injury Association (ASIA) and Thoracolumbar Injury Classification and Scoring System (TLICS) assessments were recorded [25]. Both patients met criteria for instability of the fracture requiring operative stabilization. Clinical outcomes, length of surgery, estimated blood loss and length of stay were recorded and analyzed.

We describe our surgical technique to perform a L1 corpectomy with the extreme lateral approach.

Surgical technique

Points of note

The major anatomic landmarks to consider when preparing for this surgery are the ribs, lung, diaphragm, aorta and the spinal curvature. The diaphragm will be in the surgical access path when accessing the spine for the levels from T10 to L1. The diaphragmatic tendinous attachments may be encountered down to the L3 vertebra.

Preoperative MRI should be carefully evaluated to examine for the position of the aorta, the sympathetic plexus and its relation to the psoas muscle and the spinal curvature which may place the aorta in the path of the lateral surgical corridor.

Position

After induction of general anesthesia, the patient is placed in the lateral decubitus position with the left side up. We prefer to use the left side to access the spine as the aorta and iliac arteries are more pliable and forgiving than the vena cava system and more likely to withstand surgical handling without injury. In patients with scoliosis, the aorta may lie on the lateral aspect of the vertebral bodies and thus would require access from the opposite (right) side.

The patient is positioned on the table such that the table break lies at the midpoint of the iliac crest and the greater trochanter. All pressure points are padded and the patient is secured to the table with tape at the following locations: Fig. 1a.

1. Over the iliac crest below the table break.
2. Over the thoracic region above the region of the surgical exposure.
3. From the iliac crest inferiorly securing to the foot of the table.

The bed is slightly flexed to expand the costo-pelvic interval and the intercostals. The table (not the C arm) is carefully adjusted to obtain true anteroposterior (the spinous processes should be midline and the pedicles should be equidistant from the spinous processes) and lateral (Fig. 1b).

Fluoroscopy is then utilized to mark out the fracture site on the skin, identifying the superior aspect of the disc space above and the inferior aspect of the disc space below the fractured vertebrae.

When operating within the pleural cavity (to access the spinal levels from the L1 body and above), the approach is typically in between the ribs. The incision is again marked utilizing fluoroscopy and will run parallel and in between the ribs, along the superior aspect of the inferior rib, to avoid injury to the neurovascular bundle (Fig. 2a). A chlorhexidine wipe and Chloraprep solution is used to sterilize the surgical site.

Anatomic considerations during access to the retroperitoneum

The main paired abdominal muscles include the external oblique muscles, internal oblique muscles, transversus abdominis muscles, and their respective aponeuroses, which provide core strength and protection to the abdominal wall viscera. The transversalis fascia is one of the main components that maintain structural integrity of the retroperitoneal space. A 4-cm transverse incision is made along the lateral flank at the midline level of the index vertebral body. The incision should be made parallel to the direction of the fibers of the external oblique to minimize the possibility of injury to the motor nerves supplying them. This prevents abdominal wall pseudo-hernia formation from loss of tone to these abdominal wall muscles. Blunt dissection with anterior sweeping movements of the retroperitoneal contents is then performed to enable palpation of the psoas muscle and the transverse process of the index vertebra.

Retroperitoneal access

The T12–L1 level, in our experience, can be accessed both through the transpleural route and through the diaphragm

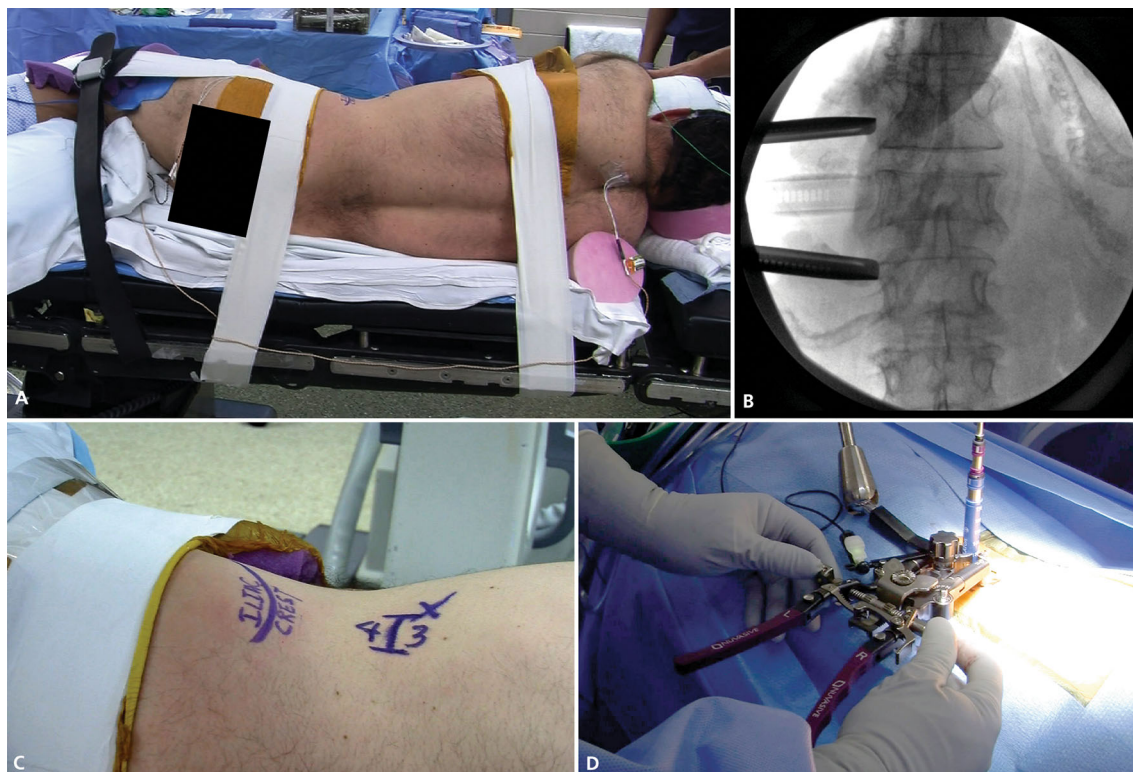


Fig. 1 **a** Operating room picture demonstrating positioning of the patient in relation to the table break. **b** AP radiograph demonstrating central spinous processes with equidistant pedicles. **d** Picture demonstrating site of incision in relation to the costal angle and the iliac

crest. **e** Operating room picture with insert demonstrating the dilator system acting as electrodes and providing an indication of the relative proximity to the nerves

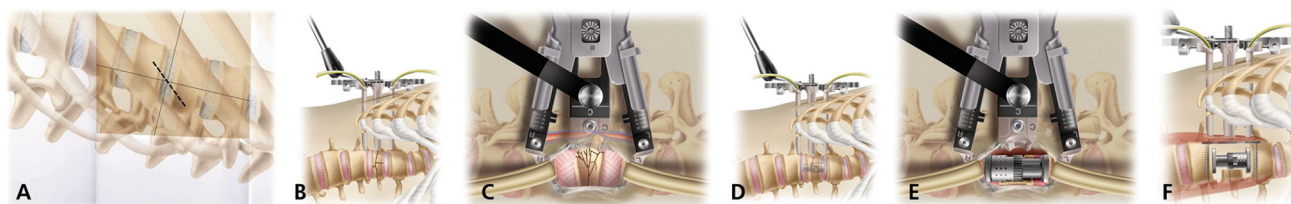


Fig. 2 **a** Animation demonstrating placement of the incision in relation to the ribs. **b, c** Animation demonstrating positioning of the dilator system and the extent of exposure obtained. The handles of the retractor are directed dorsally in this retroperitoneal access approach.

d, e Animation demonstrating dissections, preparation of end plates and placement of an expandable cage after performing the corpectomy. **f** Animation demonstrating placement of the cage and plate

in the retroperitoneal space. The levels below L1 down to the L5 superior end plate require a retroperitoneal access route. A 4-cm flank incision is performed as above to gain access to the retroperitoneal space via blunt finger dissection, carefully sweeping the abdominal contents ventrally as each layer of the lateral musculature and fascia are traversed. Loss of resistance from muscles (external oblique, internal oblique, transversalis muscle and fascia transversalis) indicates that the retroperitoneal space has been reached.

Once the tip of the transverse process is encountered, the finger is then directed medially to feel for the psoas muscle,

gently sweeping anteriorly and bluntly dissecting any fascial adhesions. The first dilator is then passed with the finger as its guide through the oblique muscle layers down to the retroperitoneal space and docked on the psoas muscle in the center of the vertebral body.

Electrophysiological monitoring

The lumbar plexus tends to lie in the posterior one third of the psoas muscle. Electrophysiological monitoring is utilized in all cases to enable safe passage of the dilators and retractor system to minimize retraction and damage to

these motor nerves. We utilize the neurovision (TM) neuromonitoring which continuously searches for the stimulus threshold that elicits an EMG response and reports this threshold both audibly and visually. As the stimulus source (the dilators and the retractor system also act as electrodes and are insulated to minimize current shunting) moves closer to the nerve, less stimulus intensity is required to elicit a response, resulting in a lower threshold, which provides an indication of the relative proximity of the dilator to the nerves (Fig. 1e). We consider threshold values of 10 mA and greater as a marker of safe distance from the nerves.

Procedure

We utilize the MaXcess retractor system (NuVasive, Inc. San Diego, CA), advancing it over the dilators and minimally expanding it to reveal the inferior aspect of the rostral vertebral body and the superior aspect of the caudal vertebral body adjacent to the fractured level (Fig. 2b, c).

The handles of the retractor system are positioned ventrally for intercostal access in the pleural cavity to enable the center blade to retract the lung and/or diaphragm during exposure of the spine. Below L1, the retractor handles are positioned posteriorly. The retractor is gently opened to expose the disc spaces above and below the index level; wanding of the blades is often required to enable full rostral–caudal exposure while limiting superficial skin and rib expansion. Depending upon the retractor positioning, either the third blade or the fourth blade can be used to ventrally retract the lung, while additional blade expanders are placed down the blades to further minimize access to visceral and pleural contents into the surgical corridor. An EMG blunt-tip probe is used to locate the laterally traversing nerve root (ideally behind the posterior retractor blade) to ensure that it lies outside the surgical corridor.

Once exposed, it is important to safely locate and sacrifice the segmental arterial branch supplying the vertebral body which takes off as a branch of the posterior intercostal artery arising from the aorta. This minimizes nuisance blood loss if it is lacerated inadvertently, but more so prevents possible avulsion of the vessel from the aorta during further dissection.

Total discectomies are then performed above and below the fractured body in routine fashion as previously described [9] (Fig. 2e).

Using punches, rongeurs, and a high-speed drill, the fractured vertebral body is removed starting centrally to create a potential space where displaced posterior fragments can be persuaded into and away from the neural elements until the underlying posterior ligament and dura is visualized. The remaining fractured body is further removed from the disc space above to below; the anterior cortical surface does not need to be removed in its entirety, as complete removal dramatically increases the possibility of a great vessel or visceral injury. The residual anterior bone can further act as a buttress to the cage and aide in surface area for arthrodesis materials. Once the corpectomy is complete, the endplates are prepared, and an expandable titanium cage filled with morselized autograft (collected during the bony removal) Fig. 2d, e is inserted, its positioning confirmed by fluoroscopy Fig. 3b, c. The cage is ideally positioned anterior to midline to make use of the greater structural integrity of the apophyseal ring as compared to that of the weaker central body. The lateral bodies of the vertebrae above and below the cage are carefully drilled flush to enable level placement of a lateral plate, which is then secured with four vertebral screws. The posterior screws are placed with bi-cortical purchase for added construct stability, while the anterior screws utilize unilateral cortical purchase, to minimize contralateral visceral or vascular injury at the point of a cortical breach. Final imaging is performed in the AP and lateral plane to confirm hardware placement, following which copious

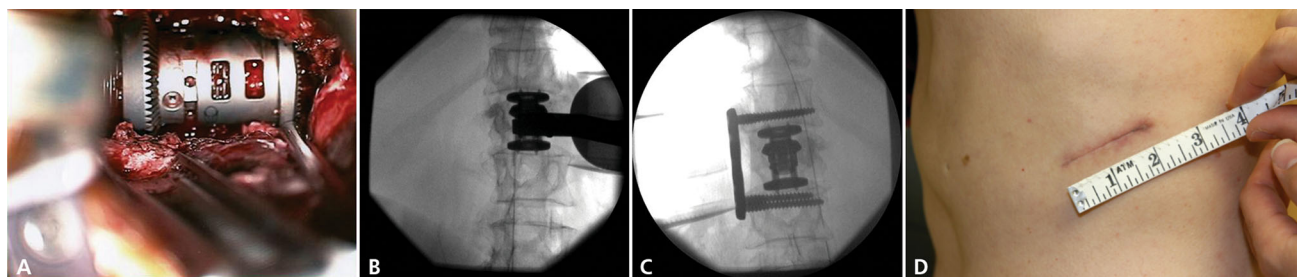


Fig. 3 **a** Intra-operative photograph of placement of the interbody expandable cage. **b** Intra-operative fluoroscopic image of interbody graft placement. **c** Intra-operative fluoroscopic image demonstrating

placement of interbody graft with lateral plate and screw reinforcement. **d** Postoperative scar of MIS approach for treatment of burst fracture in patient 1

Table 1 Key points

Left side up
Flex the table after the patient is secured with tapes on the table
Do not move the C-arm, move the table to obtain crisp endplates and midline spinous processes
Retractor handles directed posteriorly when operating in the retroperitoneal space and anteriorly when operating in the pleural cavity
Avoid injuring the neurovascular bundle when access is in between the ribs
Incision for retroperitoneal access should be made parallel to the direction of the fibers of the external oblique. Ensure good closure of the transversalis fascia
Secure the segmental vertebral vessel early in the surgery
The diaphragm may be encountered from T10 to L3 levels

irrigation and meticulous hemostasis are performed (Figs. 2f, 3a–c).

Closure

The retractor is carefully contracted and extracted under direct visualization to confirm that there is no bleeding upon its removal. If pleural opening occurred during surgical access, a red rubber catheter is placed through the defect prior to closure, following which positive pressure ventilation and suction during valsalva are used to minimize air in the intrapleural cavity. The catheter is removed through a purse-string suture prior to dermal closure. A chest radiograph should be obtained postoperatively to confirm and track pneumothorax. Table 1 enumerates the key points of the aforementioned surgical procedure.

Summary of cases

Case 1

A 52-year-old previously healthy male sustained a fall from approximately 15 feet during a hunting accident. He presented to the emergency department complaining of low back pain, but was otherwise neurologically intact (ASIA-E). CT scan demonstrated a L1 burst fracture, with retropulsion of the fragmented body causing approximately 90 % narrowing of the central canal (Fig. 4a, b).

The right T12–L1 facet joint was dislocated, and L1 pedicle fractures were present bilaterally. MRI confirmed disruption of the posterior ligamentous complex at the thoracolumbar junction; the injury was assigned a TLICS score of five [10] (Fig. 4c).

On post-trauma day 1, the patient underwent a posterior decompression and pedicle screw instrumentation from T12 to L2. Two days later, he returned to the operating room for a minimally invasive lateral transpsoas approach for the anterior construct as described above. During the dissection, a small hole in the diaphragm was required to release the soft tissue overlying the T12 vertebral body and gain access to the psoas muscle. The decompression was performed and an expandable cage, filled with an osteoconductive bone matrix, was inserted and expanded to 39 mm. During closure, a red rubber catheter was placed into the intrapleural space at the base of the diaphragm. A purse-string suture was placed around the catheter, followed by 10 s of positive pressure ventilation and subsequent removal of the catheter with immediate closure of the deep fascia. No pleural catheter was left in place. The patient did not develop a pneumothorax. Postoperative

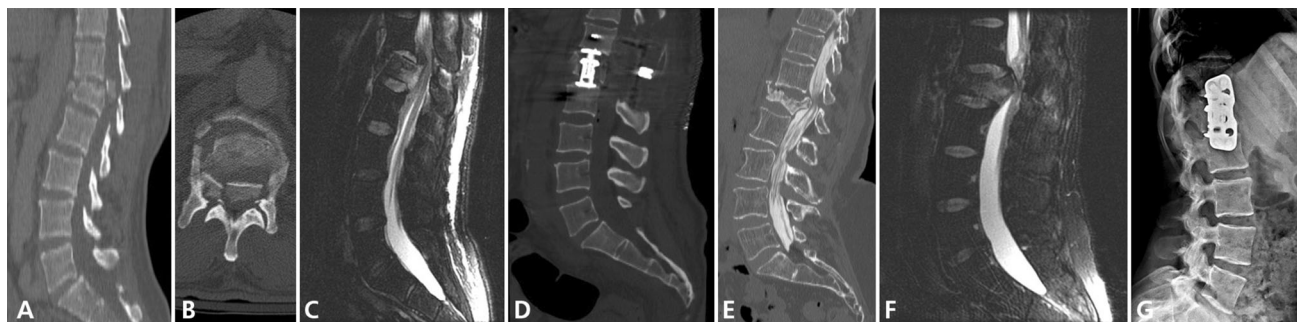


Fig. 4 **a** Sagittal CT scan demonstrating L1 burst fracture with kyphotic deformity. **b** Axial CT scan demonstrating significant retropulsion of fractured vertebral body. **c** Sagittal T2 MRI demonstrating kyphotic injury and associated significant ligamentous injury. **d** Postoperative lateral radiograph demonstrating corpectomy, cage placement and correction of kyphotic deformity. **e** Sagittal CT

myelogram demonstrating L1 burst fracture with kyphotic deformity. **f** Sagittal T2 MRI demonstrating kyphotic injury and associated significant ligamentous injury. **g** Postoperative lateral radiograph demonstrating corpectomy, cage placement and correction of kyphotic deformity

imaging demonstrated thecal sac decompression and vertebral column realignment (Fig. 4d).

Case 2

A 17-year-old woman was the restrained driver in a high-speed motor vehicle collision. She presented with severe low back pain but remained neurologically intact (ASIA-E). CT scan demonstrated an L1 burst fracture with 70 % loss of height of the vertebral body and retropulsion causing canal narrowing of 60 %, with associated right L1 pedicle and lamina fractures (Fig. 4e). MRI demonstrated a disrupted posterior ligamentous complex, for a TLICS score of 5 [10] (Fig. 4f).

On post-trauma day 2, the patient was taken to the operating room for a minimally invasive lateral transposas approach for an L1 corpectomy as detailed above. Utilizing fluoroscopy, an expandable cage, filled with osteoconductive bone matrix, was then placed and expanded to 39 mm. The lateral edge of the T12 and L2 vertebrae was drilled flat, following which a TSLP 61-mm titanium plate (Synthes, West Chester, PA) was placed using four vertebral body screws. Postoperative imaging confirmed thecal sac decompression and vertebral column realignment (Fig. 4g).

Results

There were no peri- or intra-operative complications in either case. Both patients experienced transient postoperative grade 4/5 weakness in hip flexion on the side of the psoas dilation. The operative time for case 1 was 3 h, 57 min with an estimated blood loss (EBL) of 400 mL. The patient was hospitalized for a total of 7 days (discharged 3 days following his anterior operation), followed by 7 days of inpatient rehabilitation prior to discharge home. At the last follow-up at 11 months after the surgery, the patient was neurologically intact with no back pain, and the Cobb angle measured from the superior end plate of T12 to the inferior end plate of L2 had reduced from 22° to 6°.

The total operative time for case 2 was 4 h and 42 min with an EBL of 240 mL. The hospital stay was a total of 4 days. The patient was discharged to home neurologically intact. At the last follow-up, 29 months after the surgery, the patient was neurologically intact without pain and the Cobb angle measured from the superior end plate of T12 to the inferior end plate of L2 had reduced from 20° to 16°.

Figure 3d demonstrates the cosmetic benefit of using the extreme lateral approach over the standard retroperitoneal access to decompress and reconstruct the thoracic spine.

In both cases, complete decompression of the spinal canal was achieved with correction of the kyphotic deformity.

Discussion

Surgical approaches for treating unstable thoracolumbar burst fractures can be broadly categorized as anterior, posterior, or combined approaches. Surgical intent includes decompression of neural elements, restoration of vertebral alignment, correction and prevention of kyphotic deformity, and rigid fixation to promote arthrodesis [1, 4]. We describe a minimally invasive extreme lateral approach with distinct advantages over traditional open, anterior/ anterolateral approaches.

The first widely used instrumentation for posterior stabilization of thoracolumbar burst fractures was the Harrington distraction rod system, popularized in the 1970s. The Cotrel-Dubousset hook/rod system, modified with additional hook fixation sites to improve stiffness, was subsequently shown to create a 93 % fusion rate in 48 thoracolumbar burst fractures after 21-month follow-up [11]. The extent of segmental instrumentation required in hook-rod constructs to three levels cephalad and two levels caudad to the fracture increases the stability of the construct but significantly limits the spinal motion. More recently, pedicle screw instrumentation has gained popularity in treating thoracolumbar burst fractures, allowing for rigid 3-column fixation over a shorter fusion segment [12–14]. However, short-segment posterior fusion carries an increased risk of post-traumatic kyphotic deformity compared to long-segment instrumentation [15].

Inherently, posterior approaches enable limited direct visualization during decompression of the spinal canal. Anterior decompression is thus a valuable tool when decompressing thoracolumbar burst fractures with significant canal compromise. Additionally, anterior fusion provides improved stabilization against the progression of kyphotic deformity.

An anterolateral approach to the thoracolumbar spine was first described in the 1950s by Hodgson and Stock [16], for the purpose of draining tuberculous abscesses. Bohlman [17] popularized the retroperitoneal approach to perform anterior decompression of the spinal canal in thoracolumbar burst fractures. Acute stabilization of thoracolumbar burst fractures was achieved by anterior instrumentation devices by Dunn and Kostuick-Harrington, although hardware failure occurred in greater than 10 % of cases [18, 19].

To access the anterior thoracolumbar spine from T12 to L2, the conventional open approach consists of a lateral incision over the ribs and dissection of muscular layers until exposure of the peritoneum is achieved, followed by mobilization of the diaphragm and retraction of lung parenchyma to access the retroperitoneal space [20, 21]. This approach commonly requires insertion of a chest tube

until the pleural effusion resulting from diaphragmatic dissection has drained. Complications specific to anterior spine surgery include aortic laceration (0.08 %), pneumothorax (1.8 %), and post-thoracotomy pain syndrome persisting for greater than 6 months (9 %) [6].

Anterior approaches for vertebrectomy and arthrodesis via laparoscopic and video-assisted thoracoscopic techniques has been well-described in the literature [7, 22–25]. These approaches to the anterior thoracolumbar spine have been shown to result in shorter hospitalizations when compared to open approaches [23, 26].

The extreme lateral transposas approach has been previously described for the treatment of degenerative thoracolumbar disease [9]. It is a minimally invasive approach that utilizes sequential dilation with EMG neuromonitoring to place an expandable tubular retractor. It provides the additional benefit of minimizing dissection of the great vessels and the sympathetic plexus, thus reducing the risk of vascular injury and retrograde ejaculation [17]. Its use in the treatment of traumatic thoracolumbar burst fractures has been sparsely reported in the literature. Through a small corridor, corpectomy can be performed at most levels from T12 to L4 allowing for decompression, correction of deformity, and fusion.

We present a technical report of two cases in which a minimally invasive extreme lateral approach was utilized for corpectomy, decompression of the spinal canal, placement of an interbody cage with correction of kyphotic deformity, and lateral plate and screw stabilization. In both cases, adequate visualization was achieved through a 4-cm incision and the expandable retractor in both rostral and caudal directions. Similarly, adequate decompression and visualization of the spinal canal and dura were achieved without sequelae to vascular or neural tissue. Placement of the interbody expandable cage and lateral plate and screws was also successfully performed through the confines of the expandable retractor. No further incisions were necessary. Patients were spared the morbidity of an open retroperitoneal exposure and associated risk of denervation of the abdominal musculature and the cosmetic blemish is minimal (Fig. 3d).

Neither patient suffered any intra- or peri-operative complications. Neither patient required placement of a chest tube nor suffered a postoperative pneumothorax. Both patients had transitory hip flexion weakness (4/5 strength) postoperatively related to the transposas approach, which resolved prior to discharge.

The minimally invasive lateral transposas approach has previously been described for the treatment of degenerative thoracolumbar disease and of scoliotic deformity. Our experience additionally illustrates its utility as a valuable tool in the anterior decompression and stabilization of acute thoracolumbar burst fractures. The

associated incision and tissue morbidity, recovery time, and length of stay appear to be reduced when utilizing this approach.

Conclusion

The minimally invasive extreme lateral approach for decompression and stabilization of acute burst fractures of the thoracolumbar spine is an effective treatment. Additional experience and long-term follow-up will be necessary to evaluate this approach further.

Conflict of interest None of the authors have any conflict of interest to disclose with regard to the material presented in this manuscript.

References

1. Aebi M, Etter C, Kehl T, Thalgot J (1987) Stabilization of the lower thoracic and lumbar spine with the internal spinal skeletal fixation system. Indications, techniques, and first results of treatment. *Spine* 12:544–551
2. Clohisy JC, Akbarnia BA, Bucholz RD, Burkus JK, Backer RJ (1992) Neurologic recovery associated with anterior decompression of spine fractures at the thoracolumbar junction (T12–L1). *Spine* 17:S325–S330
3. Dai LY, Jiang SD, Wang XY, Jiang LS (2007) A review of the management of thoracolumbar burst fractures. *Surg Neurol* 67:221–231 (discussion 31)
4. Denis F (1983) The three column spine and its significance in the classification of acute thoracolumbar spinal injuries. *Spine* 8:817–831
5. McDonough PW, Davis R, Tribus C, Zdeblick TA (2004) The management of acute thoracolumbar burst fractures with anterior corpectomy and Z-plate fixation. *Spine* 29:1901–1908 (discussion 9)
6. Faciszewski T, Winter RB, Lonstein JE, Denis F, Johnson L (1995) The surgical and medical perioperative complications of anterior spinal fusion surgery in the thoracic and lumbar spine in adults. A review of 1223 procedures. *Spine* 20:1592–1599
7. Kim DH, Jaikumar S, Kam AC (2002) Minimally invasive spine instrumentation. *Neurosurgery* 51:S15–S25
8. Bergey DL, Villavicencio AT, Goldstein T, Regan JJ (2004) Endoscopic lateral transposas approach to the lumbar spine. *Spine* 29:1681–1688
9. Ozgur BM, Aryan HE, Pimenta L, Taylor WR (2006) Extreme lateral interbody fusion (XLIF): a novel surgical technique for anterior lumbar interbody fusion. *Spine J* 6:435–443
10. Vaccaro AR, Lehman RA Jr, Hurlbert RJ et al (2005) A new classification of thoracolumbar injuries: the importance of injury morphology, the integrity of the posterior ligamentous complex, and neurologic status. *Spine* 30:2325–2333
11. McBride GG (1993) Cotrel-Dubousset rods in surgical stabilization of spinal fractures. *Spine* 18:466–473
12. Kramer DL, Rodgers WB, Mansfield FL (1995) Transpedicular instrumentation and short-segment fusion of thoracolumbar fractures: a prospective study using a single instrumentation system. *J Orthop Trauma* 9:499–506
13. Markel DC, Graziano GP (1995) A comparison study of treatment of thoracolumbar fractures using the ACE Posterior Segmental Fixator and Cotrel-Dubousset instrumentation. *Orthopedics* 18:679–686

14. Parker JW, Lane JR, Karaikovic EE, Gaines RW (2000) Successful short-segment instrumentation and fusion for thoracolumbar spine fractures: a consecutive 41/2-year series. *Spine* 25:1157–1170
15. Tezeren G, Kuru I (2005) Posterior fixation of thoracolumbar burst fracture: short-segment pedicle fixation versus long-segment instrumentation. *J Spinal Disord Tech* 18:485–488
16. Hodgson AR, Stock FE (1956) Anterior spinal fusion a preliminary communication on the radical treatment of Pott's disease and Pott's paraplegia. *Br J Surg* 44:266–275
17. Bohlman HH, Freehafer A, Dejak J (1985) The results of treatment of acute injuries of the upper thoracic spine with paralysis. *J Bone Joint Surg Am* 67(3):360–369
18. Dunn HK (1984) Anterior stabilization of thoracolumbar injuries. *Clin Orthop Relat Res* (189):116–124
19. Kostuik JP (1983) Anterior spinal cord decompression for lesions of the thoracic and lumbar spine, techniques, new methods of internal fixation results. *Spine* 8:512–531
20. Gumbs AA, Bloom ND, Bitan FD, Hanan SH (2007) Open anterior approaches for lumbar spine procedures. *Am J Surg* 194:98–102
21. Westfall SH, Akbarnia BA, Merenda JT et al (1987) Exposure of the anterior spine. Technique, complications, and results in 85 patients. *Am J Surg* 154:700–704
22. Anand N, Regan JJ (2002) Video-assisted thoracoscopic surgery for thoracic disc disease: classification and outcome study of 100 consecutive cases with a 2-year minimum follow-up period. *Spine* 27:871–879
23. Cunningham BW, Kotani Y, McNulty PS et al (1998) Video-assisted thoracoscopic surgery versus open thoracotomy for anterior thoracic spinal fusion. A comparative radiographic, biomechanical, and histologic analysis in a sheep model. *Spine* 23:1333–1340
24. Escobar E, Transfeldt E, Garvey T, Ogilvie J, Graber J, Schultz L (2003) Video-assisted versus open anterior lumbar spine fusion surgery: a comparison of four techniques and complications in 135 patients. *Spine* 28:729–732
25. Scheufler KM (2007) Technique and clinical results of minimally invasive reconstruction and stabilization of the thoracic and thoracolumbar spine with expandable cages and ventrolateral plate fixation. *Neurosurgery* 61:798–808 (discussion 9)
26. McAfee PC, Regan JR, Zdeblick T et al (1995) The incidence of complications in endoscopic anterior thoracolumbar spinal reconstructive surgery. A prospective multicenter study comprising the first 100 consecutive cases. *Spine* 20:1624–1632