

# The lumbosacral plexus: anatomic considerations for minimally invasive retroperitoneal transpsoas approach

Patrick Guérin · Ibrahim Obeid · Anouar Bourghli ·  
Thibault Masquefa · Stéphane Luc · Olivier Gille ·  
Vincent Pointillart · Jean-Marc Vital

Received: 2 May 2011 / Accepted: 21 September 2011 / Published online: 5 October 2011  
© Springer-Verlag 2011

## Abstract

**Purpose** The minimally invasive transpsoas approach can be employed to treat various spinal disorders, such as disc degeneration, deformity, and lateral disc herniation. With this technique, visualization is limited in comparison with the open procedure and the proximity of the lumbar plexus to the surgical pathway is one limitation of this technique. Precise knowledge of the regional anatomy of the lumbar plexus is required for safe passage through the psoas muscle. The primary objective of this study was to determine the anatomic position of the lumbar plexus branches and sympathetic chain in relation to the intervertebral disc and to define a safe working zone. The second objective was to compare our observations with previous anatomical studies concerning the transpsoas approach.

**Methods** A total of 60 lumbar plexus in 8 fresh cadavers from the Department of Anatomy were analyzed in this study. Coronal and lateral X-Ray images were obtained before dissection in order to eliminate spine deformity or fracture. All cadavers were placed in a lateral decubitus position with a lateral bolster. Dissection of the lumbar

plexus was performed. All nerve branches and sympathetic chain were identified. Intervertebral disc space from L1L2 to L4L5 was divided into four zones. Zone 1 being the anterior quarter of the disc, zone 2 being the middle anterior quarter, zone 3 the posterior middle quarter and zone 4 the posterior quarter. Crossing of each nervous branch with the disc was reported and a safe working zone was determined for L1L2 to L4L5 disc levels. A safe working zone was defined by the absence of crossing of a lumbar plexus branch.

**Results** No anatomical variation was found during blunt dissection. As described previously, the lumbar plexus is composed of the ventral divisions of the first four lumbar nerves and from contributions of the sub costal nerve from T12. The safe working zone includes zones 2 and 3 at level L1L2, zone 3 at level L2L3, zone 3 at level L3L4, and zone 2 at level L4L5. No difference was observed between right and left sides as regards the relationships between the lumbar plexus and the intervertebral disc.

**Conclusion** We observed some differences concerning the safe working zone in comparison with other cadaveric studies. The small number of cadaveric specimens used in anatomical studies probably explains these differences. The minimally invasive transpsoas lateral approach was initially developed to reduce the complications associated with the traditional procedure. The anatomical relationships between the lumbar plexus and the intervertebral disc make this technique particularly risky a L4L5. Alternative techniques, such as transforaminal interbody fusion (TLIF), posterior lumbar interbody fusion (PLIF) or anterior interbody fusion (ALIF) should be used at this level.

**Keywords** Anatomy · Lumbar plexus · Minimally invasive spinal surgery · Transpsoas lateral approach · Safe working zone · Lumbar fusion

---

P. Guérin · A. Bourghli · J.-M. Vital  
Laboratoire d'Anatomie Médico-Chirurgicale Appliquée  
Université Victor Segalen Bordeaux 2, 146 rue Léo Saignat,  
33000 Bordeaux, France

P. Guérin (✉) · I. Obeid · A. Bourghli · T. Masquefa ·  
S. Luc · O. Gille · V. Pointillart · J.-M. Vital  
Spinal Unit 1, Department of Orthopaedic Surgery,  
University Hospital of Bordeaux, Place Amélie Raba-Léon,  
33076 Bordeaux Cedex, France  
e-mail: patrick.guerin@chu-bordeaux.fr;  
pguerin\_patrick@yahoo.fr

## Introduction

There has been a recent surge in the use of minimally invasive approaches to the lumbar spine for interbody fusion. The minimally invasive transpsoas approach can be employed to treat various spinal disorders, such as disc degeneration, deformity, and lateral disc herniation. This technique reduces recovery time, blood loss and tissue damage [1]. The minimally invasive transpsoas approach is based on the psoas muscle technique. It provides direct lateral access to the intervertebral disc space [15]. The patient is placed in lateral decubitus and a lateral bolster is put in place in order to open the space between the 12th rib and the iliac crest. A small lateral incision is made (3–5 cm). After dissecting external oblique, internal oblique and transverse muscles, the psoas is split using a K-wire. Under X-Ray guidance, K-wire is inserted into the intervertebral disc space. Dilatation tubes are then used and a specific retractor is put in place. A working space can thus be created. After discectomy and endplate preparation, an interbody cage is inserted. Transpsoas approach only allows access from L1L2 to L4L5 levels. The L5S1 approach is impossible given the location of the iliac crest. During minimally invasive transpsoas approach, visualization is limited compared with an open procedure and the proximity of the lumbar plexus to the surgical pathway is

one limitation of this technique. Neural injury during transpsoas approach is a well-known complication and neuro-monitoring is a useful adjunct that to avoid these adverse events [5, 12]. Precise knowledge of the regional anatomy of the lumbar plexus is required for safe passage through the psoas.

The lumbar plexus is composed of the ventral divisions of the first four lumbar nerves and from contributions of the sub costal nerve from T12 (Table 1). They form the iliohypogastric nerve (T12–L1), the ilio-inguinal nerve (L1), the genito-femoral nerve (L1–L2), the femoral nerve (L2–L4), the lateral femoral cutaneous nerve (L2L3), the obturator nerve (L2L4) and some muscular branches (T12–L4). The ventral division of the fourth lumbar nerve passes branches communicating with the sacral plexus (lumbosacral trunk).

Accurate knowledge of anatomic relationships between lumbar plexus and intervertebral disc is essential to perform interbody fusion by minimally invasive retroperitoneal transpsoas access. The primary objective of this study was to analyze the anatomical location of the lumbar plexus relative to the intervertebral disc spaces using cadaveric dissections and to delineate a safe zone. The second objective was to compare our observations with previous anatomical studies concerning the transpsoas approach. [2, 3, 14, 18]

**Table 1** Lumbar plexus: innervated muscles and cutaneous branches

Nerve	Segment	Innervated muscles	Cutaneous branches
Lumbar plexus			
Iliohypogastric	T12–L1	Transversus abdominis Abdominal internal oblique	Anterior cutaneous ramus Lateral cutaneous ramus
Ilioinguinal	L1		Anterior scrotal nerves in males Anterior labial nerves in females
Genitofemoral	L1, L2	Cremaster (males)	Femoral ramus Genital ramus
Lateral femoral cutaneous	L2, L3		Lateral femoral cutaneous
Obturator	L2–L4	Obturator externus Adductor longus Gracilis Pectineus Adductor magnus	Cutaneous ramus
Femoral	L2–L4	Iliopsoas Pectineus Sartorius Quadriceps femoris	Anterior cutaneous branches Saphenous
Muscular branches	T12–L4	Psoas major Quadratus lumborum Iliacus Lumbar intertransverse	

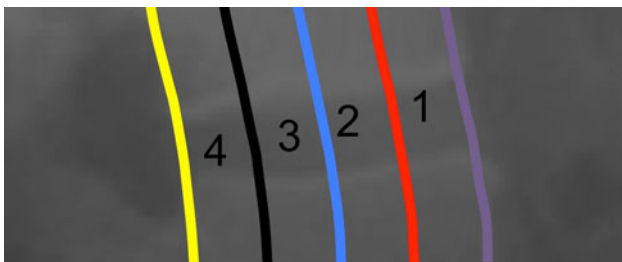## Methods

A total of 60 lumbar plexus (8 on the right and 8 on the left) in 8 fresh cadavers (70–83 years of age at time of death) from the Department of Anatomy were analyzed in this study. Coronal and lateral X-Ray images were obtained before dissection in order to eliminate spine deformity or fracture. All cadavers were placed in the lateral decubitus position with a lateral bolster. A lateral incision was made from the 11th rib to the iliac crest. The 12th rib was always removed in order to correctly expose the L1L2 intervertebral disc space. After dissection of external oblique, internal oblique and transversalis muscles, the retroperitoneal space was exposed. The intestines were retracted ventrally and the psoas muscle was identified. Each intervertebral level was marked with a K-wire under X-ray guidance.

Dissection of the lumbar plexus was performed and all nerve branches were identified. The location of the sympathetic chain was also reported. The intervertebral disc space from L1L2 to L4L5 was divided into four zones. Zone 1 was the anterior quarter of the disc, zone 2 the middle anterior quarter, zone 3 the posterior middle quarter and zone 4 the posterior quarter (Fig. 1). This methodology was previously described by Uribe et al. [18]. The distribution of the sympathetic chain and the lumbar plexus (iliohypogastric, ilioinguinal, genitofemoral, femoral, lateral femoral cutaneous, obturator nerves and muscular branches) was recorded for each intervertebral level. Crossing of each nervous branch with the disc was reported and a safe working zone was determined from L1L2 to L4L5 disc levels. A safe working zone was defined by the absence of crossing of a lumbar plexus branch.

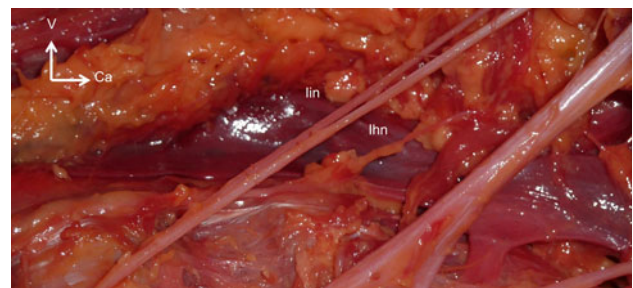
## Results

No anatomical variation was found during blunt dissection. As described previously [6], the lumbar plexus was

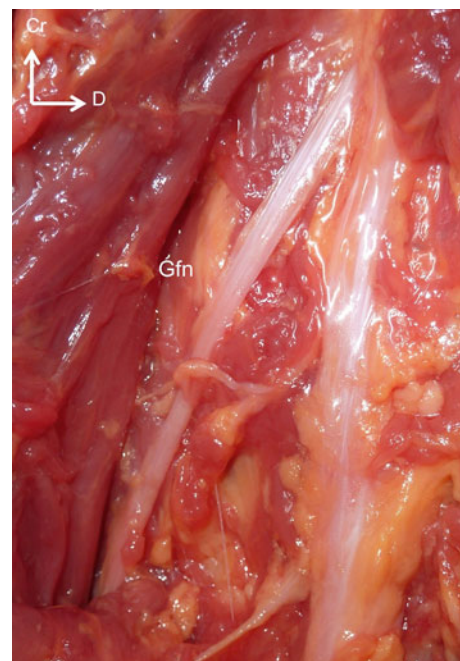


**Fig. 1** Lateral X ray Intervertebral disc space was divided in 4 zone: zone 1 (anterior quarter), zone 2 (middle anterior quarter), zone 3 (posterior middle quarter), zone 4 (posterior quarter). Crossing of each nervous branch with the disc was reported and a safe working zone were determined from L1L2 to L4L5 disc levels

composed of the ventral divisions of the first four lumbar nerves and from contributions from the sub costal nerve from T12. They form the iliohypogastric nerve (T12–L1, Fig. 2), the ilio-inguinal nerve (L1, Fig. 2), the genito-femoral nerve (L1–L2, Fig. 3), the femoral nerve (L2–L4, Fig. 4), the lateral femoral cutaneous nerve (L2L3, Fig. 5), the obturator nerve (L2L4, Fig. 5) and some muscular branches (T12–L4, Fig. 6). The ventral division of the fourth lumbar nerve passed communicating branches with the sacral plexus (lumbosacral trunk). At level L1L2, all the nerve branches were found in zone 4 (posterior quarter) and the sympathetic chain in zone 1. The safe working zone at this level includes zones 2 and 3 (anterior and posterior middle quarter). At level L2L3, the sympathetic chain was found in zone 1, the genitofemoral nerve in zone 2 and the other branches in zone 4. The safe working zone at this level was represented by zone 3 (posterior middle



**Fig. 2** Right lateral view in craniocaudal direction from left to right, ilio-hypogastric nerve (Ihn) and ilio-inguinal nerve (Iin)



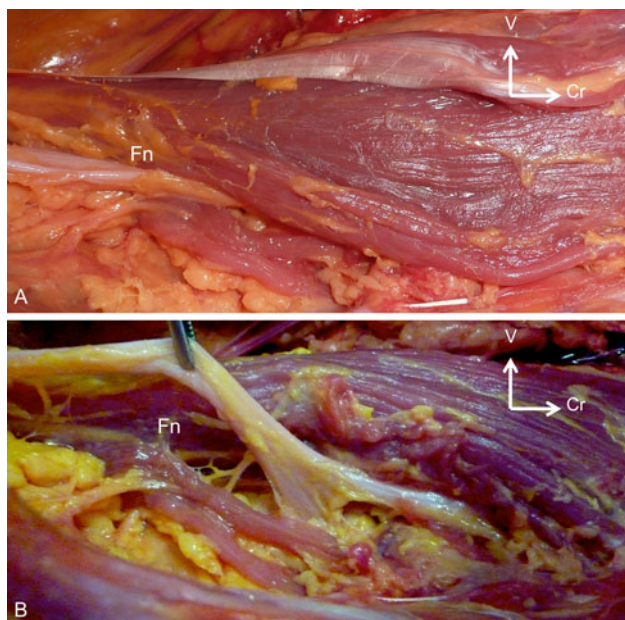
**Fig. 3** Left lateral view in craniocaudal direction from up to down, genito-femoral nerve (Gfn)



quarter). At level L3L4, the sympathetic chain was found in zone 1, genitofemoral in zone 1 for 7 cadavers (it was found in zone 2 for one specimen on the right and left sides) and the other branches in zone 4. The safe working zone at this level was represented by zone 3 (posterior middle quarter).

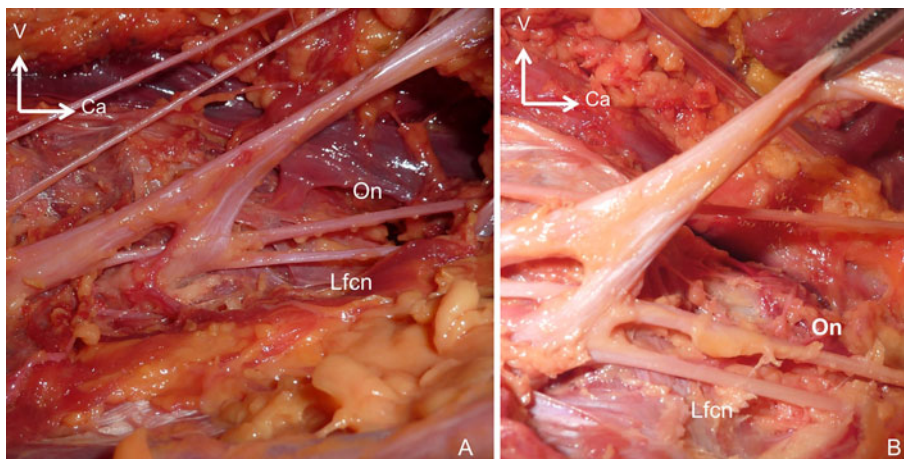
At L4L5 level, the sympathetic chain and genitofemoral nerve were found in zone 1, and the other branches in zones 3 and 4. The safe working zone at this level was represented by zone 2 (middle anterior quarter, Fig. 7).

Data concerning safe working zones for the different intervertebral levels can be seen in Fig. 8a–c. No difference was observed between right and left sides as concerns the lumbar plexus relationship with the intervertebral disc.



**Fig. 4** Left lateral view in craniocaudal direction from right to left, femoral nerve (Fn)

**Fig. 5** Right lateral view in craniocaudal direction from left to right, lateral femoral cutaneous nerve (Lfcn) and obturator nerve (On)

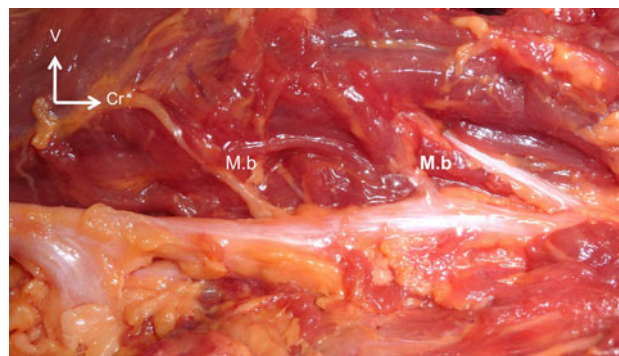


## Discussion

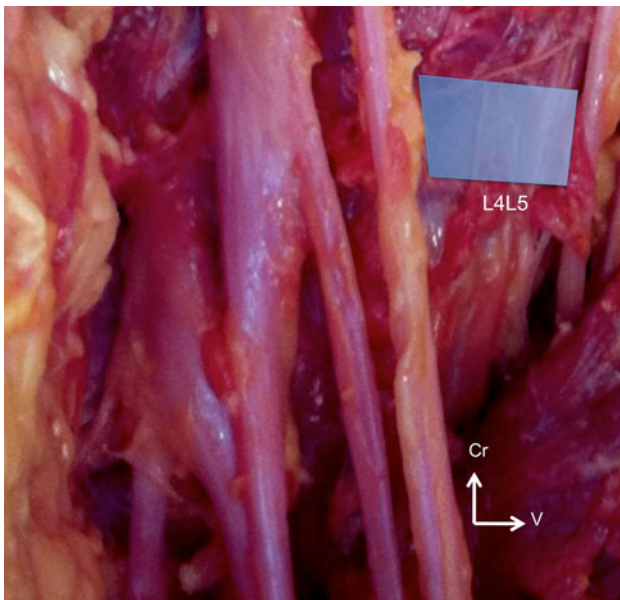
Lumbar spinal interbody fusion is a common treatment for spinal disorders. It can be achieved via an anterior, posterior or transforaminal approach. Interbody graft increases the rates of fusion and provides anterior column support. Lateral interbody fusion via the minimally invasive retroperitoneal approach was introduced by Ozgur and Pimenta [15]. It was developed to avoid complications associated with traditional approaches.

Only anterior fusion such as ALIF (anterior lumbar interbody fusion) is possible using this recent technique but it avoids large vessel manipulation. The majority of complications with ALIF are associated with surgical exposure. Many vascular complications during ALIF have been reported [7].

In 2004, Bergey et al. [4] described a direct endoscopic lateral transpoas approach to the lumbar spine as an alternative to the standard endoscopic anterior approach, which requires mobilization of the sympathetic plexus and the great vessels. In this study, 21 patients underwent lumbar spinal fusion via a lateral endoscopic transpoas



**Fig. 6** Left lateral view in craniocaudal direction from right to left, muscular branches (Mb)

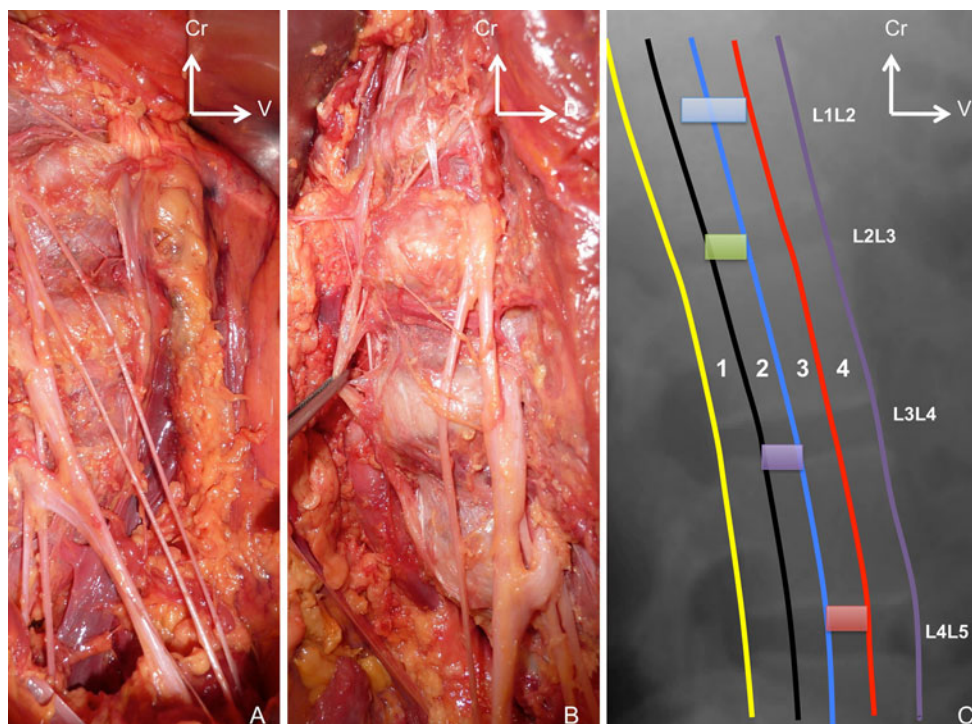


**Fig. 7** Right lateral view in craniocaudal direction from up to down, safe working zone at L4L5 level

approach. There were no vascular injuries but six patients (30%) developed transient postoperative groin/thigh paresthesias.

Previous MRI study has reported a significant narrowing of the safe zone at L4–L5 level [9, 11, 17]. Hasegawa et al. reported that the length of the nerve roots increased progressively from L1 to L5. Furthermore, the nerve root origin was situated at a more cephalad level for the caudal nerve roots [10]. Some authors have proposed preoperative planning using MRI acquisition. The relative position of neurovascular structures in relation to the intervertebral disc is calculated and the safe zone is then determined. The theoretical risk of neurovascular injury during transpsoas approach can be evaluated during this planning stage. The principal problem associated with this safe zone delineation is the inability to locate the branches of the lumbar plexus and the sympathetic trunk [9, 11, 16, 17].

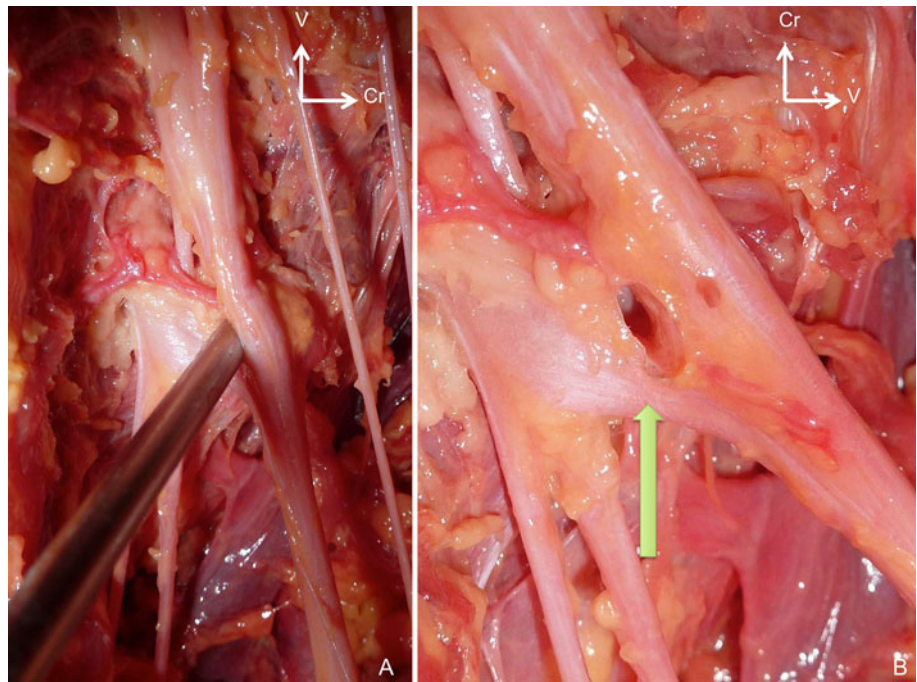
Ventral nerve roots and the lumbar plexus can be damaged during the penetration and retraction of psoas muscle. Retroperitoneal large vessels can be injured during discectomy, vertebral endplate preparation and interbody cage insertion. During this procedure, it is difficult to choose the entry point at which to pass through the psoas muscle. Furthermore, assessing the placement of the cage without direct visualization of the neurovascular structures is a challenge. If the entry point is too anterior or posterior, that may increase the risk of vessel or nerve injuries (Fig. 9), respectively.



**Fig. 8** Lumbar plexus. **a** Right side right lateral view in craniocaudal direction from up to down. **b** Left side left lateral view in craniocaudal direction from up to down. **c** Representation of safe zone for L1L2, L2L3, L3L4, L4L5 levels



**Fig. 9** Injury of femoral nerve with K-wire



Gu et al. [8] determined with cadaveric study, a safe working zone for performing lateral interbody fusion. This area was located between the anterior border of the lumbar nerve and the posterior border of the sympathetic trunk. The location of the genitofemoral nerve was responsible for a narrowing of the safe zone at L2L3 level. Moro et al. [14] described the location of the lumbar plexus from L1L2 to L5S1 intervertebral disc. Six cadavers were analyzed in their study. They recommended splitting the psoas more anteriorely than the dorsal quarter of the lumbar vertebral body from the cranial third of the L3 vertebral body and above to prevent nerve injuries. In another anatomical study, Benglis et al. [3] reported progressive ventral migration of the lumbar plexus on the disc space from L1L2 to L4L5. In this study, they reported the results as the ratio of the location of the plexus from the posterior endplate to the total length of the intervertebral disc space. They concluded that lumbar plexus may be at risk of injury during L4L5 lateral transpsoas approach and that positioning the dilators and the retractor in a posterior position may result in neural injury. Uribe et al. delineate safe working zone with respect of lumbar plexus branches. They dissected five cadaveric specimens. In their study, the safe zones at the intervertebral disc from L1L2 to L3L4 were at the midpoint of zone 3 and the safe zone at L4L5 was at the zone 2/zone 3 demarcation [18]. Benagan et al. [2] conducted an anatomical study on eight cadaveric specimens. They recreated the lateral transpsoas approach and identified the structure at risk for each intervertebral

level. They concluded that there is no zone of absolute safety when using the lateral transpsoas approach [2].

Understanding the structure and course of lumbosacral plexus is important during minimally invasive transpsoas approach. Matejcik et al. conducted anatomical study on 50 cadaveric specimens. They dissected lumbosacral plexi for each specimen. They described anatomical deviations in formation of neural roots and nerves of lumbar plexus. These variations can have an influence on safe zone position [13]. We observed some differences concerning the safe working zone. The small number of cadaveric specimen used in anatomical study probably explains these differences. Another important point is the fact that there may be differences between cadaveric specimens and patients concerning the tissue planes and flexibility [2].

The minimally invasive transpsoas lateral approach was initially developed to decrease complications associated with the traditional procedure. The anatomical relationships of the lumbar plexus with the intervertebral disc make this technique particularly risky at L4L5. Alternative techniques, such as transforaminal interbody fusion (TLIF), posterior lumbar interbody fusion (PLIF) or anterior interbody fusion (ALIF) should be used at this level. Our work represents a small contribution to anatomical knowledge of the lumbar plexus and its relation with the intervertebral space. Anatomical landmarks were also established in the normal aligned spine. The anatomical location of the plexus on the scoliotic spine needs to be assessed by further cadaveric studies.

**Acknowledgments** Etienne Delamarre and technicians from Department of Anatomy.

**Conflict of interest** None.

## References

- Anand N, Baron EM, Thaiyananthan G, Khalsa K, Goldstein TB (2008) Minimally invasive multilevel percutaneous correction and fusion for adult lumbar degenerative scoliosis: a technique and feasibility study. *J Spinal Disord Tech* 21:459–467
- Banagan K, Gelb D, Poelstra K, Ludwig S (2011) Anatomic mapping of lumbar nerve roots during a direct lateral transpsoas approach to the spine: a cadaveric study. *Spine*. doi: [10.1097/BRS.0b013e3181ec5911](https://doi.org/10.1097/BRS.0b013e3181ec5911)
- Benglis DM, Vanni S, Levi AD (2009) An anatomical study of the lumbosacral plexus as related to the minimally invasive transpsoas approach to the lumbar spine. *J Neurosurg Spine* 10:139–144
- Bergey DL, Villavicencio AT, Goldstein T, Regan JJ (2004) Endoscopic lateral transpsoas approach to the lumbar spine. *Spine* 29:1681–1688
- Dakwar E, Cardona RF, Smith DA, Uribe JS (2010) Early outcomes and safety of the minimally invasive, lateral retroperitoneal transpsoas approach for adult degenerative scoliosis. *Neurosurg Focus* 28:E8
- Dakwar E, Vale FL, Uribe JS (2011) Trajectory of the main sensory and motor branches of the lumbar plexus outside the psoas muscle related to the lateral retroperitoneal transpsoas approach. *J Neurosurg Spine* 14:290–295
- Fantini GA, Pappou IP, Girardi FP, Sandhu HS, Cammisa FP Jr (2007) Major vascular injury during anterior lumbar spinal surgery: incidence, risk factors, and management. *Spine* 32:2751–2758
- Gu Y, Ebraheim NA, Xu R, RezcAllah AT, Yeasting RA (2001) Anatomic considerations of the posterolateral lumbar disk region. *Orthopedics* 24:56–58
- Guérin P, Obeid I, Gille O, Bourghli A, Luc S, Pointillart V, Cursolle JC, Vital JM (2011) Safe working zones using the minimally invasive lateral retroperitoneal transpsoas approach: a morphometric study. *Surg Radiol Anat*. doi: [10.1007/s00276-011-0798-6](https://doi.org/10.1007/s00276-011-0798-6)
- Hasegawa T, Mikawa Y, Watanabe R, An HS (1996) Morphometric analysis of the lumbosacral nerve roots and dorsal root ganglia by magnetic resonance imaging. *Spine* 21:1005–1009
- Kepler CK, Bogner EA, Herzog RJ, Huang RC (2010) Anatomy of the psoas muscle and lumbar plexus with respect to the surgical approach for lateral transpsoas interbody fusion. *Eur Spine J*. doi: [10.1007/s00586-010-1593-5](https://doi.org/10.1007/s00586-010-1593-5)
- Knight RQ, Schwaegler P, Hanscom D, Roh J (2009) Direct lateral lumbar interbody fusion for degenerative conditions: early complication profile. *J Spinal Disord Tech* 22:34–37
- Matejčík V (2010) Anatomical variations of lumbosacral plexus. *Surg Radiol Anat* 32(4):409–414
- Moro T, Kikuchi S, Konno S, Yaginuma H (2003) An anatomic study of the lumbar plexus with respect to retroperitoneal endoscopic surgery. *Spine* 28:423–428
- Ozgur BM, Aryan HE, Pimenta L, Taylor WR (2006) Extreme Lateral Interbody Fusion (XLIF): a novel surgical technique for anterior lumbar interbody fusion. *Spine J* 6:435–443
- Park DK, Lee MJ, Lin EL, Singh K, An HS, Phillips FM (2010) The relationship of intrapsoas nerves during a transpsoas approach to the lumbar spine: anatomic study. *J Spinal Disord Tech* 23:223–228
- Regev GJ, Chen L, Dhawan M, Lee YP, Garfin SR, Kim CW (2009) Morphometric analysis of the ventral nerve roots and retroperitoneal vessels with respect to the minimally invasive lateral approach in normal and deformed spines. *Spine* 34:1330–1335
- Uribe JS, Arredondo N, Dakwar E, Vale FL (2010) Defining the safe working zones using the minimally invasive lateral retroperitoneal transpsoas approach: an anatomical study. *J Neurosurg Spine* 13:260–266