

Minimally Invasive Retropleural Approach for Central Thoracic Disc Herniation

Authors

M. K. Kasliwal, H. Deutsch

Affiliation

Department of Neurosurgery, RUSH University Medical Center, Chicago, IL, USA

Key words

- thoracic disks
- discectomy
- central herniation
- minimally invasive approach
- retropleural approach

Abstract

Background: The management of symptomatic thoracic disc herniation (TDH) has evolved tremendously ever since the first laminectomy was performed. The last decade has witnessed the evolution of minimally invasive approaches for TDH most of which have been posterior/posterolateral. Traditional anterior approaches involve a thoracotomy or more recently, thoracoscopic techniques. The authors describe a less invasive anterior retropleural surgical approach to address central thoracic disc herniations which is less extensive than a thoracotomy and allows better anterior access than posterior or posterolateral approaches. The retropleural approach allows the use of the operative microscope with a tubular retractor in the anterior thoracic spine.

Material and Methods: 7 patients with central disc herniation who were managed with the minimally invasive lateral retropleural approach from 2007–2010 at our institution were included in the study. Surgical technique consisted of a lat-

eral position followed by retropleural exposure through tubular retractor system without the need of intraoperative lung collapse. Clinical details including age, sex, clinical presentation, surgical details, complications and outcome at last follow-up were analyzed.

Results: Patients age ranged in age from 30 to 70 years (mean: 52 years). The duration of symptoms ranged from 4 days to 3 years. All patients presented with thoracic myelopathy on physical examination. The average length of stay in the hospital was 2.6 days (range: 1–4 days). Follow-up was available for all the patients. Myelopathy was assessed by the Nurick scale. On examination, 3 of 7 patients improved by one point on the Nurick scale. No patient deteriorated after surgery. There were no complications related to the approach.

Conclusions: A minimally invasive retropleural approach using tubular retractor system for central thoracic disc herniation is feasible and may be a less invasive anterior alternative to a thoracotomy.

Bibliography

DOI <http://dx.doi.org/10.1055/s-0031-1284400>
 Minim Invas Neurosurg 2011;
 54: 167–171
 © Georg Thieme Verlag KG
 Stuttgart · New York
 ISSN 0946-7211

Correspondence

H. Deutsch, MD

Department of Neurosurgery
 Suite 970
 RUSH University Medical Center
 Chicago
 IL 60612
 USA
 Tel.: +1/312/942 6644
 Fax: +1/312/942 2176
 Harel_Deutsch@rush.edu

Introduction

Symptomatic thoracic disc herniation (TDH) is a relatively uncommon condition [1]. While many thoracic disks are incidental, some present with progressive thoracic myelopathy. Initial surgical approaches involving thoracic laminectomies were associated with poor results because of lack of direct access to the disk herniation and the danger in retracting the thoracic spinal cord [2]. Transpedicular and posterolateral approaches yield better clinical outcomes and are preferable when possible [3–10]. Central disk herniations are often difficult to reach without spinal cord retraction even through a posterolateral approach. A thoracotomy allows an anterior approach but has significant morbidity [7, 11, 12].

Thoracoscopic techniques are less invasive but require specialized instruments and a significant learning curve [13–15]. In this paper we describe an approach allowing using a tubular retractor system placed in the retropleural plane. The approach allows for anterior access and the use of the microscope with standard instruments.

Materials and Methods

Between 2007 and 2010, 7 patients (4 males and 3 females) underwent the minimally invasive retropleural approach (• Fig. 1) for central TDH at the author's institution. Patients ranged in age from 30 to 70 years (mean: 52 years). The duration of symptoms ranged from 4 days to 3 years.

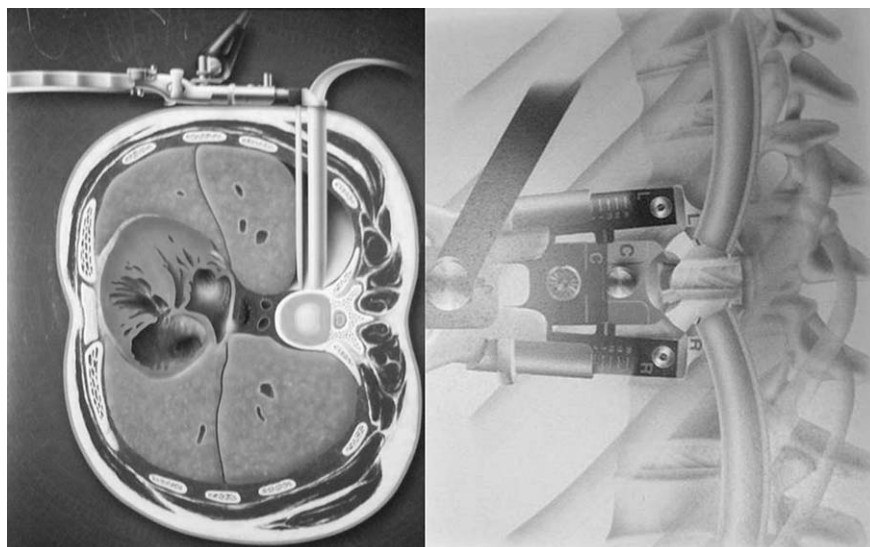


Fig. 1 Illustration showing the outline of trajectory involved in the minimally invasive lateral transthoracic approach for thoracic disc herniation.

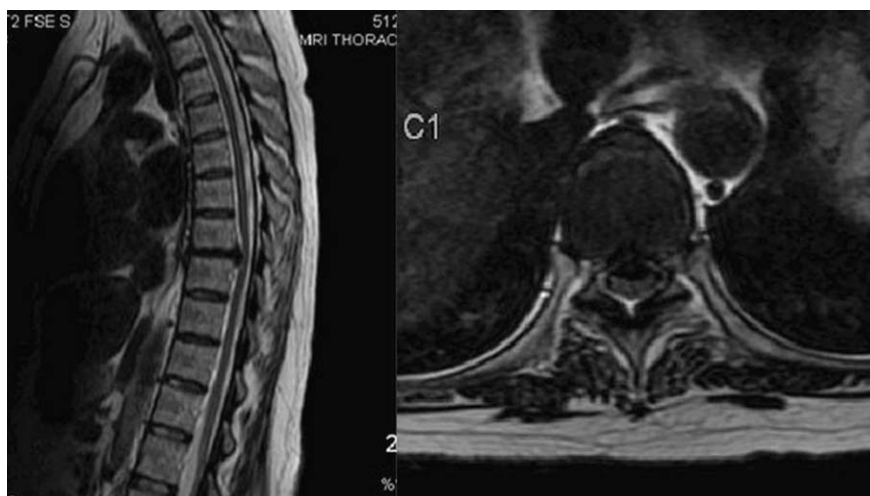


Fig. 2 Preoperative sagittal (*left*) and axial (*right*) MRI showing a centrally herniated calcified T7-8 thoracic disc.

S. No	Age (yrs)	Sex	Level	Myelopathy	Radiculopathy	Pre op Nurick's grade	LOS (days)	Post op Nurick's grade
1	61	M	T7-T8	Yes	Yes	4	2	3
2	67	M	T10-11	Yes	Yes	1	3	1
3	49	M	T8-9, T9-10	Yes	No	3	3	2
4	70	F	T9-10	Yes	No	4	4	3
5	35	F	T7-8	Yes	Yes	1	3	1
6	54	M	T8-9	Yes	No	5	2	5
7	30	F	T6-7	Yes	Yes	1	1	1

Table 1 Clinical characteristics, operative data, and outcomes of patients who underwent the minimally invasive retropleural approach for TDH.

Thoracic disc herniations were identified at the following levels: T6-7 (1 patient), T7-8 (2 patients), T8-9 (2 patients), T9-10 (2 patients) and T10-11 (1 patient). 1 patient had 1 disc herniations. Preoperative MRI was available in all patients which confirmed the diagnosis of a central disc thoracic disc herniation (● Fig. 2). The technique used was a minimally invasive retropleural approach. The details of the clinical presentation and outcome of all the 7 patients are shown in ● Table 1.

Technique

After induction of general anesthesia and insertion of a Foley catheter the patient is positioned in the lateral decubitus position with the left/right side up with an axillary roll on a standard

Stryker operating room table. All pressure points are padded adequately and SSEP monitoring is performed intraoperatively. The fluoroscopic C-arm is positioned and draped to allow acquisition of lateral and anteroposterior X-ray images of the operative area. The patient is positioned in as true a lateral position as possible and the incision is marked with fluoroscopy so as to be directly above the posterior vertebral body border and spinal canal. Following appropriate localization of the intervertebral disc space of interest using fluoroscopy an incision 2 cm in length is made and carried down using a monopolar device to expose the rib. The space between the ribs is limited and often some of the rib is removed using a Kerrison rongeur to widen the interspace. Blunt dissection between the pleura and the rib is then carried

down as far as possible down to the head of the rib. Some tears in the pleura are often appreciated. The rib head usually lies over the pedicle and the spinal canal. The initial dilator (MaXcess System, NuVasive, Inc.) is then introduced into the thoracic cavity and passed posteriorly along the ribs down the intersection of the rib head and spine (◉ Fig. 3). After docking the initial dilator in position, the level is confirmed using fluoroscopy (◉ Fig. 4). After inserting further dilators, the MaXcess Driver (NuVasive, Inc.) is introduced and centered over the disc space. Again fluoroscopy is used to confirm the desired level by counting up from the sacrum below (◉ Fig. 4). Both AP and lateral fluoroscopy is often used to localize the level because of the difficulty of localizing levels in the thoracic spine. The retractors are then secured to the table in the standard fashion. The retractor is also expanded. The blades are often over 13 cm in length and the operative distance is long. The operative microscope is brought in. The intercostal arteries are usually in the midpoint of the vertebral body and are best avoided.

The remaining pleura is opened using a monopolar device. The heads of the ribs are identified. After removing the head of the rib with a pneumatic drill, the pedicle is exposed. Partial drilling of the pedicle exposes the dura and the bulging disc. The disk is removed using a combination of a Kerrison punch, curettes, and pituitary rongeurs to adequately decompress the dura (◉ Fig. 5). Often the disk is calcified and we use a curette to separate the disk from the spinal cord and push the fragments into the disk cavity. A red rubber catheter is then inserted in the thoracic cavity. The wound is then closed in layers with several interrupted 2-0 Vicryl sutures used for the musculature; the red rubber catheter is pulled out at the closure of the subcutaneous tissue sucking the air inside. Subcutaneous tissue is closed with 3-0 vicryl sutures followed by application of Dermabond over the skin. No chest tube is placed.

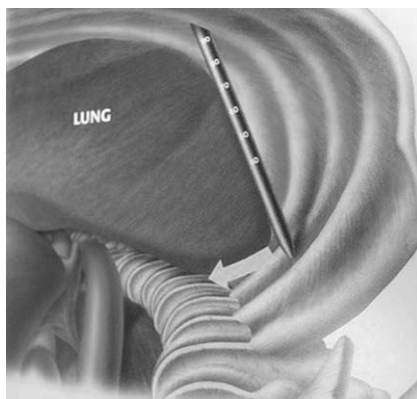


Fig. 3 Diagram showing the initial dilator being introduced (MaXcess System, NuVasive, Inc.) into the thoracic cavity and passed posteriorly along the ribs down the intersection of the rib head and spine.

Results



All patients underwent discectomy using the retropleural approach as described. No patient required any intra- or postoperative blood transfusion. The average blood loss was 180 mL (range: 150–250 mL). The average length of stay in the hospital was 2.6 days (range: 1–4 days). Patients with severe myelopathy required inpatient rehabilitation and physical therapy. Follow-up was available for all the 7 patients and ranged from 12 months to 24 months (average: 16 months).

Neurological outcome was assessed using Nurick's scale. 3 of 7 patients improved one point on the Nurick scale (◉ Table 1). No patient deteriorated after surgery. There were no complications related to the approach. Pain improved in all 4 patients with radiculopathy. Average pain scores were assessed using a numerical pain score (0–10). Numerical pain scores improved from a preoperative average of 7.2–3.1 at the last follow-up. Postoperative MRI imaging was done in all of the patients, documenting good decompression (◉ Fig. 6).

Discussion



Thoracic disc herniations are rare compared to cervical and lumbar disc herniations. Most thoracic disc herniations are asymptomatic.

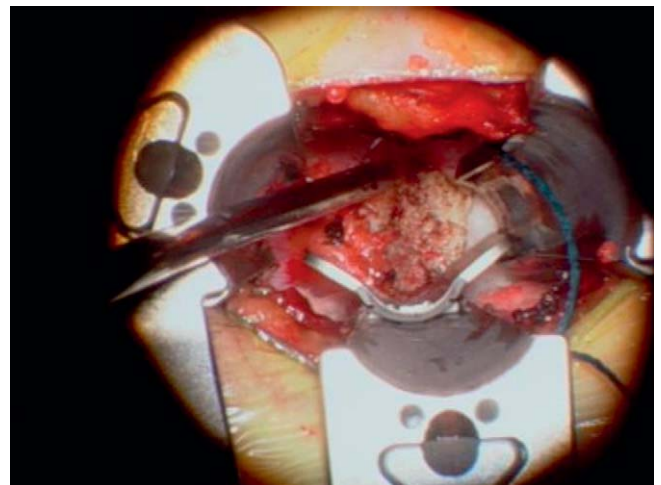


Fig. 5 Intraoperative photograph showing the disc being removed using a combination of a Kerrison punch and pituitary rongeur adequately decompressing the dura.

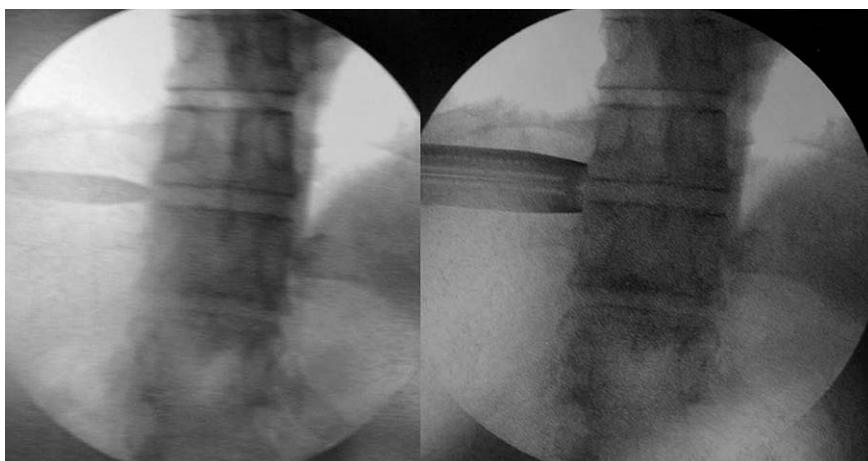


Fig. 4 Intraoperative fluoroscopy confirming the position of the initial dilator (left) and later after introduction of the MaXcess driver (right).

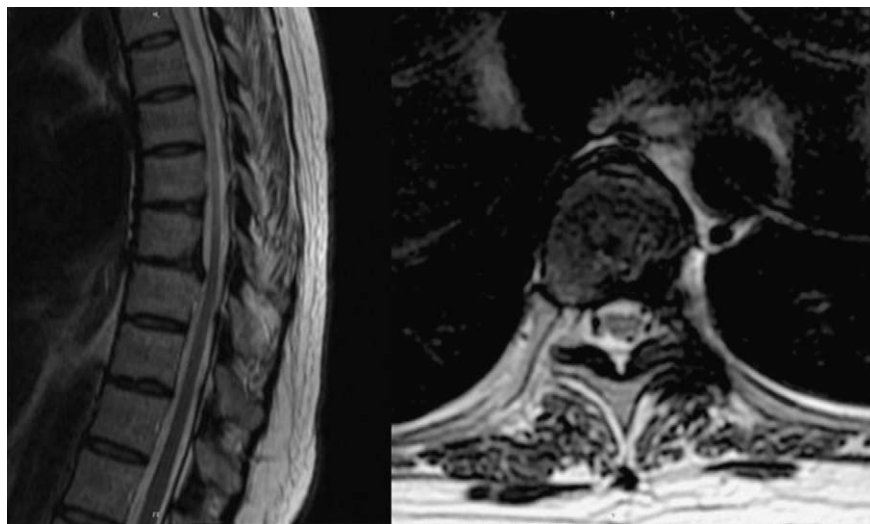

Fig. 6 Postoperative sagittal (*left*) and axial (*right*) MR image showing good neural decompression after surgery with post operative changes.

matic and discovered incidentally. Significant large thoracic disk herniations can result in progressive lower extremity myelopathy with or without radiculopathy. Laminectomy was the preferred surgical approach for TDH in the initial stages and was associated with neurological worsening in up to one third of the cases [2]. Unacceptable outcomes were instrumental in the development of alternative surgical strategies for managing TDH. Unlike the lumbar spine where thecal sac retraction is feasible, the thoracic spine cannot be retracted without serious sequelae.

Various surgical techniques developed over time including: posterolateral (costotransversectomy, transpedicular); lateral (extracavitary,) and anterior (transthoracic and thoracoscopic surgery) [8,9,13–23]. Laterally located disks are often best approached through a posterolateral approach. Truly central disk herniations are difficult to directly remove with a posterolateral approach. Transthoracic thoracotomy approaches provide excellent visualization of the ventral aspect of the thoracic spine, without the associated risk of spinal cord manipulation [13,14,24–26]. The need for a large skin incision, lung collapse and retraction, rib resection, and muscle dissection for open thoracic approaches contribute to postoperative pulmonary dysfunction, pain, and increased morbidity [7,11,27]. To offset the disadvantages of an open thoracotomy approach, thoracoscopic approaches were developed for TDH [13–15,24–26]. Disadvantages of the thoracoscopic approach include the lack of three-dimensional visualization, the need of intraoperative collapse of one lung, steep learning curve, and the need for a postoperative chest tube with its attendant morbidity [1,5].

The last decade has witnessed a dramatic upsurge in the application of minimally invasive surgery for the management of TDH leading to a reduction of overall postoperative morbidity and improved clinical outcomes [3,5,14,15,28,30]. Most of the evolution in surgical techniques has been centered on development of posterolateral approaches, from mini open to percutaneous and endoscopic discectomy through the transpedicular, transfacet and transforaminal routes [3,5,15,28,29,31]. The retropleural approach described in this paper allows for a minimally invasive anterior exposure of the thoracic spinal cord with the use of a tubular retractor system. The approach retains the advantages of thoracoscopic and open thoracotomy in terms of excellent visualization of the disc space from in front of the dura and spinal cord avoiding spinal cord manipulation. The disk is removed under safe and appropriate visualization. The advan-

tages of this technique include a small single incision (2 cm) as compared to the much larger open thoracotomy incision. There is no need for the multiple incisions used in thoracoscopy thus reducing the postoperative pain. Also advantageous is the use of the operative microscope. The microscope allows for three-dimensional imaging and familiar hand-eye coordination skills most spine surgeons are familiar with. The learning curve is less than with the thoracoscopic approaches. The advantages over the posterior approaches includes less postoperative pain due to the avoidance of muscle and ligamentous trauma and better anterior visualization of the disc space. Disadvantages of this approach include the long operating corridor. The distance is often over 13 cm and longer instruments may be needed. The narrow channel also makes bleeding and other complications difficult to address which may potentially require conversion to an open thoracotomy. No conversion was however needed in our experience.

There were no complications in our series. The average length of stay in the hospital was 2.6 days in our series which is significantly shorter compared to patients undergoing a thoracotomy surgery [13]. The hospitalization is comparable to that for patients with minimally invasive posterior or posterolateral approaches [15]. Various complications can occur after TDH surgery including spinal cord injury, postoperative neuralgia, cerebrospinal fluid leak, postsurgical kyphosis and pneumothorax depending on the approach chosen [13,27]. Wrong level surgery, which remains a possibility with all spine surgeries, is more common in the thoracic spine especially in patients with TDH due to the lack of obvious vertebral body deformation, and interference due to scapular shadows in the midthoracic spine which can make interpretation of fluoroscopy difficult. Percutaneous placement of radiopaque markers at the pedicle of interest as described recently by Binnings et al. [32] may be a useful preoperative localizing measure to avoid this complication.

Conclusions

▼ The thoracic retropleural approach described by the present authors uses a series of muscle dilators, a tubular retractor, and an operating microscope to perform an anterior discectomy without the morbidity of the traditional transthoracic thoracotomy approaches. Less muscle and bony resection is required due

to the use of the tubular retractor system. Familiarity with the use of a tubular retractor system and the operating microscope makes the technique easier for most surgeons compared to a thoracoscopic technique. Although no fusion is required as the major part of the disc is left behind, it does provide an option of placing an interbody graft if required.

Conflict of Interest: None

References

- 1 Arce CA, Dohrmann GJ. Thoracic disc herniation. Improved diagnosis with computed tomographic scanning and a review of the literature. *Surg Neurol* 1985; 23: 356–361
- 2 Logue V. Thoracic intervertebral disc prolapse with spinal cord compression. *J Neurol Neurosurg Psychiatry* 1952; 15: 227–241
- 3 Chi JH, Dhall SS, Kanter AS et al. The mini-open transpedicular thoracic discectomy: surgical technique and assessment. *Neurosurg Focus* 2008; 25: E5
- 4 Delfini R, Di Lorenzo N, Ciappetta P et al. Surgical treatment of thoracic disc herniation: a reappraisal of Larson's lateral extracavitary approach. *Surg Neurol* 1996; 45: 517–522
- 5 Jho HD. Endoscopic microscopic transpedicular thoracic discectomy. Technical note. *Neurosurg Focus* 1998; 4: e7
- 6 Maiman DJ, Larson SJ, Luck E et al. Lateral extracavitary approach to the spine for thoracic disc herniation: report of 23 cases. *Neurosurgery* 1984; 14: 178–182
- 7 Mulier S, Debois V. Thoracic disc herniations: transthoracic, lateral, or posterolateral approach? A review. *Surg Neurol* 1998; 49: 599–606
- 8 Patterson RH Jr, Arbit E. A surgical approach through the pedicle to protruded thoracic discs. *J Neurosurg* 1978; 48: 768–772
- 9 Simpson JM, Silveri CP, Simeone FA et al. Thoracic disc herniation. Reevaluation of the posterior approach using a modified costotransversectomy. *Spine (Phila Pa 1976)* 1993; 18: 1872–1877
- 10 Stillerman CB, Chen TC, Day JD et al. The transfacet pedicle-sparing approach for thoracic disc removal: cadaveric morphometric analysis and preliminary clinical experience. *J Neurosurg* 1995; 83: 971–976
- 11 Currier BL, Eismont FJ, Green BA. Transthoracic disc excision and fusion for herniated thoracic discs. *Spine (Phila Pa 1976)* 1994; 19: 323–328
- 12 Perot PL Jr, Munro DD. Transthoracic removal of midline thoracic disc protrusions causing spinal cord compression. *J Neurosurg* 1969; 31: 452–458
- 13 Anand N, Regan JJ. Video-assisted thoracoscopic surgery for thoracic disc disease: Classification and outcome study of 100 consecutive cases with a 2-year minimum follow-up period. *Spine (Phila Pa 1976)* 2002; 27: 871–879
- 14 Burke TG, Caputy AJ. Treatment of thoracic disc herniation: evolution toward the minimally invasive thoracoscopic technique. *Neurosurg Focus* 2000; 9: e9
- 15 Perez-Cruet MJ, Kim BS, Sandhu F et al. Thoracic microendoscopic discectomy. *J Neurosurg Spine* 2004; 1: 58–63
- 16 Capener N. The evolution of lateral rhachotomy. *J Bone Joint Surg Br* 1954; 36-B 173–179
- 17 Larson SJ, Holst RA, Hemmy DC et al. Lateral extracavitary approach to traumatic lesions of the thoracic and lumbar spine. *J Neurosurg* 1976; 45: 628–637
- 18 Mack MJ, Regan JJ, Bobechko WP et al. Application of thoracoscopy for diseases of the spine. *Ann Thorac Surg* 1993; 56: 736–738
- 19 Mack MJ, Regan JJ, McAfee PC et al. Video-assisted thoracic surgery for the anterior approach to the thoracic spine. *Ann Thorac Surg* 1995; 59: 1100–1106
- 20 Ransohoff J, Spencer F, Siew F et al. Transthoracic removal of thoracic disc. Report of three cases. *J Neurosurg* 1969; 31: 459–461
- 21 Rosenthal D, Dickman CA. Thoracoscopic microsurgical excision of herniated thoracic discs. *J Neurosurg* 1998; 89: 224–235
- 22 Rosenthal D, Rosenthal R, de Simone A. Removal of a protruded thoracic disc using microsurgical endoscopy: A new technique. *Spine (Phila Pa 1976)* 1994; 19: 1087–1091
- 23 Sundaresan N, Shah J, Feghali JG. A transsternal approach to the upper thoracic vertebrae. *Am J Surg* 1984; 148: 473–477
- 24 Dickman CA, Mican CA. Multilevel anterior thoracic discectomies and anterior interbody fusion using a microsurgical thoracoscopic approach. Case report. *J Neurosurg* 1996; 89: 104–109
- 25 Dickman CA, Rosenthal D, Regan JJ. Reoperation for herniated thoracic discs. *J Neurosurg* 1999; 91 (2 Suppl): 157–162
- 26 Ferson PF, Landreneau RJ, Dowling RD et al. Comparison of open versus thoracoscopic lung biopsy for diffuse infiltrative pulmonary disease. *J Thorac Cardiovasc Surg* 1993; 106: 194–199
- 27 Fessler RG, Sturgill M. Review: complications of surgery for thoracic disc disease. *Surg Neurol* 1998; 49: 609–618
- 28 Choi KY, Eun SS, Lee SH et al. Percutaneous endoscopic thoracic discectomy; transforaminal approach. *Minim Invas Neurosurg* 2010; 53: 25–28
- 29 Eichholz KM, O'Toole JE, Fessler RG. Thoracic microendoscopic discectomy. *Neurosurg Clin N Am* 2006; 17: 441–446
- 30 Perez-Cruet MJ, Foley KT, Isaacs RE et al. Microendoscopic lumbar discectomy: technical note. *Neurosurgery* 2002; 51 (5 Suppl): S129–S136
- 31 Isaacs RE, Podichetty VK, Sandhu FA et al. Thoracic microendoscopic discectomy: a human cadaver study. *Spine (Phila Pa 1976)* 2005; 30: 1226–1231
- 32 Binning MJ, Schmidt MH. Percutaneous placement of radiopaque markers at the pedicle of interest for preoperative localization of thoracic spine level. *Spine (Phila Pa 1976)* 2010; 35: 1821–1825