A Cadaveric Radiographic Analysis on the Effect of Extreme Lateral Interbody Fusion Cage Placement With Supplementary Internal Fixation on Indirect Spine Decompression

German A. Marulanda, MD, Aniruddh Nayak, MS,† Ryan Murtagh, MD,‡ Brandon G. Santoni, PhD,† James B. Billys, MD,§ and Antonio E. Castellvi, MD§*

Study Design: Cadaveric Biomechanical and Radiographic Analysis.

Objective: The purpose of this study was to quantify the changes in intervertebral height and lateral and central recess areas afforded by lateral interbody fusion cages with 2 supplemental forms of internal fixation in cadaveric specimens.

Background Data: When conservative treatment for symptomatic lumbar stenosis fails, traditional intervention has been direct posterior decompression. The minimally invasive, lateral transpsoas approach may be a viable alternative to direct decompression by providing restoration of the foraminal and intervertebral dimensions, yet few reports have examined the anatomic and radiographic changes that occur using this technique.

Methods: Computed tomography (CT) scans were taken of 18 intact lumbar (L1–S1) cadaveric specimens under a 400 N preload. Intervertebral height, foraminal areas, and canal area were measured at L3–L4 and L4–L5. Thereafter, the cadaveric specimens were instrumented with lateral cages placed in the central or posterior third of the disk space at L3–L4 and L4–L5 and either (1) lateral plate (n = 9) or (2) bilateral posterior pedicle screw fixation (n = 9). All constructs were again subjected to a 400 N preload, postinstrumentation CT scans were taken, and changes in intervertebral height and lateral and central recess areas were calculated.

Results: There was no effect of cage placement on any radiographic metric of indirect decompression for either fusion construct. In the lateral plate and pedicle screw groups, respectively, significant increases in average posterior disk height (30.9%, 60.1%), average right (35.3%, 61.5%) and left foraminal area (48.3%, 57.8%), and average canal area (32.3%, 33.3%) were observed. Pedicle screw instrumentation afforded a significantly greater increase in average posterior disk height and foraminal area compared with the lateral plate group, though there was no difference in the average increase in canal area afforded by either form of fixation.

Conclusions: The radiographic results reported here using a cadaveric model add validity to the underlying rationale described for the minimally invasive lateral approach technique. Increases in disk height, foraminal and canal areas were not dependent on cage positioning within the disk space. As intraoperative placement of a cage in the central portion of the disk is an easier and safer technique, our results suggest that central placement may be preferable in a clinical setting.

Key Words: lateral transpsoas approach, lumbar stenosis, indirect decompression, computed tomography, intervertebral height, foraminal area, canal area

(*J Spinal Disord Tech* 2014;27:263–270)

Lumbar spinal stenosis is a worldwide prevalent and debilitating condition affecting an estimated 400,000 adults in the United States alone. The negative impact on quality of life and the elevated burden on healthcare economics of this condition have been extensively reported. In addition to hypertrophy of the facet joints and the associated bony encroachment, soft tissue impingement, osteophyte formation, and disk herniation are some of the most predominant causes of lumbar spinal stenosis and thecal sac compression in the central, lateral recess, and foraminal areas.

When primary nonoperative interventions fail, surgical techniques such as direct laminectomy/laminotomy, facetectomy, and foraminotomy procedures are generally performed. These surgical approaches to obtain neural decompression have been associated with complications such as bleeding, epidural hematoma, deep venous thrombosis, dural tear, cerebrospinal fluid leak, infection, nerve root injury, epidural fibrosis, iatrogenic instability,

Received for publication October 2, 2012; accepted January 7, 2013.
From the *Florida Orthopedic Institute and Moffitt Cancer Center; †Phillip Spiegel Orthopaedic Research Laboratory, Foundation for Orthopaedic Research & Education; ‡University Diagnostic Institute; and §Center for Spinal Disorders, Florida Orthopaedic Institute, Tampa, FL.
Supported by an unrestricted research grant from NuVasive Inc. (San Diego, CA).
The authors declare no conflict of interest.
Reprints: German A. Marulanda, MD, Combined Spine Fellowship Program, Florida Orthopedic Institute and Moffitt Cancer Center, Tampa, FL 33637 (e-mail: germarulo@hotmail.com).

and recurrence of symptoms.[1–4] In addition, as resection of the elements results in loss of mechanical spinal stability associated with the aforementioned open surgical procedures, wide bone decompression is commonly augmented with supplemental instrumentation and fusion. Fusion may also be indicated so as to restore disk height and correction for coronal and sagittal misalignment, as decompression alone in cases of malalignment has been shown to be less effective than fusion at alleviating pain and function.[5]

In an attempt to minimize the reported complications of current approaches to neural decompression, surgeons have explored less invasive techniques. The extreme lateral interbody fusion procedure has been described as an alternative, MIS approach to anterior column stabilization in degenerated, deformed, and traumatic conditions in the thoracolumbar spine.[6–8] The procedure has proposed advantages over the conventional direct anterior lumbar interbody fusion techniques including preservation of the anterior longitudinal ligament (ALL) as well as some of the posterior and anterior annulus. Because the approach permits the removal of sufficient amount of the disk material and subsequent placement of a larger interbody implant that spans the dense ring apophysis rather than lodging in the central weaker portions of the vertebral endplate, a larger surface area for indirect decompression and fusion, if so desired, is afforded by the minimally invasive technique.[7,9,10] Authors in favor of the technique report that restoration of disk height and correction of alignment can be better achieved through the ligamentotaxis allowed by intact ALL and posterior longitudinal ligament (PLL).[10,11]

Despite reports of relief of both back and leg pain using this technique,[7,12] there exists a paucity of reports in the literature examining the anatomic, biomechanical, radiographic, and clinical changes in patients undergoing the procedure. The purpose of this study is to report on a cadaveric model of the lateral approach and the effects of cage placement within the disk space (central vs. posterior) and supplemental internal fixation options (lateral plate vs. pedicle screw + rods) on the preoperative and postoperative radiographic variables that serve as reliable metrics of indirect decompression. Our study aims to better characterize the anatomic changes that result from the minimally invasive technique.

MATERIALS AND METHODS

Specimen Preparation

Eighteen (n = 18) lumbar specimens (L1–S1) were dissected from fresh-frozen cadaveric specimens (11 males, 7 females; average age, 57.7 ± 9.8 y; range, 30–69 y). Anterior-posterior and lateral radiographs were taken to confirm that the procured specimens were free of deformity, excessive degeneration, prior instrumentation, and prior surgery. Specimens were cleaned and denuded of musculature and adipose tissue taking care to retain all ligamentous structures. Bone mineral density values were assessed by dual energy x-ray absorptiometry (Lunar Prodigy; GE Healthcare, Madison, WI), with average bone mineral density values of 1.00 ± 0.2 g/cm^2 (range, 0.76–1.49 g/cm^2) and average T-score of −1.8 (range, 2.4 to −3.9).

Lumbar specimens were rigidly potted at the cephalad and caudal (L1 and S1) ends using interference screws and high-strength resin. All cadaveric specimens were kept hydrated at all times with regular spraying with 0.9% saline. Specimens were also thoroughly sprayed down with 0.9% saline before freezing for storage. The intact lumbar spine specimens (n = 18) subsequently underwent computed tomography (CT) scanning. After intact CT scans, specimens were kept frozen until day of instrumentation. Before extreme lateral interbody fusion (XLIF) cage implantation and lateral or posterior instrumentation, all specimens were thawed out overnight (8–10 h) at room temperature (~25°C). The instrumented lumbar spine specimens (n = 18) again underwent CT scanning. All CT scans (preinstrumentation and postinstrumentation) were taken with the spine under 400 N compressive preload as described in the following section.

Technique for Application of Axial, Compressive Load to Lumbar Constructs

In order to simulate the loads experienced by the lumbar spine in the standing position and allow for the consequent reorientation of the spinal elements (disk/facet joints etc.) and neuro-foraminal changes, a 400 N follower preload was applied along the lordotic curve of the cadaver lumbar spines. This procedure of follower load application along the sagittal plane was in compliance with the technique proposed by Patwardhan et al.[13]

Using preload hooks attached bilaterally at each vertebral level, high-strength nylon cables and a custom-designed fixture, cadaver spines were preloaded to 400 N on a materials testing frame (TestResources, Model 800L, Shakopee, MN; Fig. 1). While under 400 N of applied tensile load, the nylon cable was locked into position using a crimping mechanism that gripped the cable firmly against the potted ends. By locking it in position, the deformation and tension in the cable was maintained throughout. This procedure was performed on all cadaver spines in the intact condition and after instrumentation, before and during CT scanning.

Surgical Technique

After initial CT scanning of the intact lumbar spines, the specimens were randomly allocated to 1 of the following test conditions (Fig. 2): (1) 2-level XLIF implant (CoRoent XL; NuVasive Inc., San Diego, CA) at L3–L4 and L4–L5 supplemented with a lateral plate (XLP Plate; NuVasive Inc.) at each level (n = 9); (2) 2-level XLIF implant at L3–L4 and L4–L5 supplemented with bilateral pedicle screws (SpheRx, DBR II, NuVasive) at each level (n = 9). We chose to study the 2-level model of lateral interbody cage placement and supplemental fixation given the increase in use of such constructs clinically. Thus, a total of 36 lumbar levels were instrumented. Within the



FIGURE 1. Illustration of the preload set-up. Lumbar spine constructs were rigidly coupled to the load cell of a materials testing machine. High-strength nylon cable, which was passed through eyelets that were threaded bilaterally into each vertebral body, was attached to the load cell and actuator of the machine which applied 400 N of tension to the cable. With the cable in tension, the crimp clamps were secured about the cable rendering the lumbar constructs in a state of compression for computed tomography scanning.

lateral plate and bilateral pedicle screw groups, cages at both levels were either placed in the central third or the posterior third of the disk space (Fig. 3). Cages were placed in the same positions (central or posterior) at both the L3–L4 and L4–L5 levels for each specimen. Appropriate placement of the cage in the central or posterior aspects of the disk space was subjectively judged by the instrumenting surgeon while under fluoroscopy. The surgical procedure was initiated with a lateral discectomy to remove sufficient disk material and prepare the inferior and superior vertebral endplates similar to clinical practice. The interbody cage was 18-mm wide in the anterior-posterior direction and made from polyetheretherketone with the lateral length and height dimensions of the cage determined by anatomy. The ALL, PLL, and anterior annulus were left intact, such that when the interbody cage was inserted into the disk space, the longitudinal ligaments (ALL, PLL) stretched due to resultant distraction. Lateral plate and posterior pedicle screw/rod hardware instrumentation was facilitated with fluoroscopy and all procedures were performed by board-certified spine surgeons experienced with the lateral approach technique.

Radiographic Analysis

For all cases, intact and instrumented, CT scans were taken at 0.625 mm slice thickness (GE Lightspeed QX/i; GE Healthcare, Waukesha, WI). Images were then transferred electronically to a Vitrea 3-D workstation (Vital Images Inc., Minnetonka, MN). Axial images were reconstructed into sagittal and coronal planes. Disk space heights were measured and recorded in the midsagittal plane using the Vitrea measuring tool. The sagittal images were the rotated to show the greatest foraminal area in the oblique sagittal plane. The greatest foraminal area was also measured and obtained on this same image. Measurements were subsequently made in the contralateral foramen using similar technique. Subsequently, analysis of the spinal canal area were made at the level of the disk for the instrumented functional spinal units (FSUs) using the axial images. Measurements were taken from the posterior margin of the disk space to the anterior margin of the ligamentum flavum in the midline and recorded. All radiographic dimensions were measured in triplicate (Fig. 4) on a standardized radiology workstation. Radiographic measurements were taken independently by a fellowship-trained neuroradiologist, an orthopedic resident, and a fellowship-trained board-certified spine surgeon to elucidate the effect of XLIF cage placement within the disk space on radiographic indices of indirect decompression at the L3–L4 and L4–L5 levels. Means from the 3 independent measurements were used for all statistical analyses.

Statistical Analysis

All data are reported as mean ± SD. The effect of central versus posterior interbody cage placement within the lateral plate and pedicle screw groups was compared with a 2-sided, 2-tailed *t* test. Changes relative to baseline in disk height, foraminal area, and canal area after lateral interbody cage placement and lateral plate or pedicle screw instrumentation were compared with a 2-sided, paired *t* test. Relative changes in radiographic outcome measures between the lateral plate and pedicle screw/rod instrumentation groups were compared with a 2-sided, 2 sample *t* test. Significance was set at $\alpha = 0.05$ level and all comparisons were performed with SYSTAT 13 statistical software (Systat Software Inc., Chicago, IL).

RESULTS

Of the lumbar levels (n = 36) implanted with XLIF cages, 5 (n = 5, 13.9%) levels sustained endplate fracture (inferior level: n = 4, 80%; superior level: n = 1, 20%, total n = 5 fractured endplate levels) as evidenced on lateral radiographs taken post instrumentation. Fracture occurred in 1 (n = 1) specimen in the XLIF cage + pedicle

FIGURE 2. Lateral radiographs of the extreme lateral interbody fusion cage + lateral plate (left) and bilateral pedicle screw (right) constructs.

screw/rod group and in 4 (n = 4) XLIF cage + lateral plate specimens. The average T-score of the vertebral bodies that sustained endplate fracture was −1.4 ± 2.6 (range, −3.5 to 2.9). In the post hoc analysis of the radiographic data, it was noted that the CT-based measurements at these levels were significantly altered as a result of the endplate fracture. Resultantly, radiographic data from each of these levels was removed from further statistical analysis, leaving 17 and 14 levels for analysis in the pedicle screw and lateral plate groups, respectively.

In the lateral plate constructs, evaluation of the pre-XLIF and post-XLIF cage instrumentation CT scans of the lumbar spines under 400 N of compressive preload indicated that there was no effect of cage placement (central vs. posterior) on central disk height or posterior disk height ($P = 0.413$ and 0.618, respectively), right or left foraminal area ($P = 0.918$ and 0.094, respectively), or canal area ($P = 0.326$), averaging over the L3–L4 and L4–L5 levels. Similar findings were observed for pedicle screw constructs for central and posterior disk height ($P = 0.361$ and 0.129, respectively), right and left foraminal area ($P = 0.329$ and 0.543, respectively) and canal area ($P = 0.908$). All subsequent comparisons were made after averaging over XLIF cage placement within the disk space.

In the XLIF cage + lateral plate constructs, posterior disk height was significantly increased by 30.9% from 6.8 ± 1.6 to 8.9 ± 1.4 mm ($P < 0.001$). Significant increases in right and left foraminal area ($P = 0.002$ and < 0.001, respectively) as well as canal area ($P < 0.001$) were also observed in the lateral plate constructs with XLIF cages (Fig. 5). In the XLIF cage + bilateral pedicle screw/rod constructs, posterior disk height was significantly increased by 60.1% from 5.6 ± 2.1 to 9.0 ± 1.7 mm ($P < 0.001$). Significant increases in right and left foraminal area ($P < 0.001$ and $P < 0.001$, respectively) as well as canal area

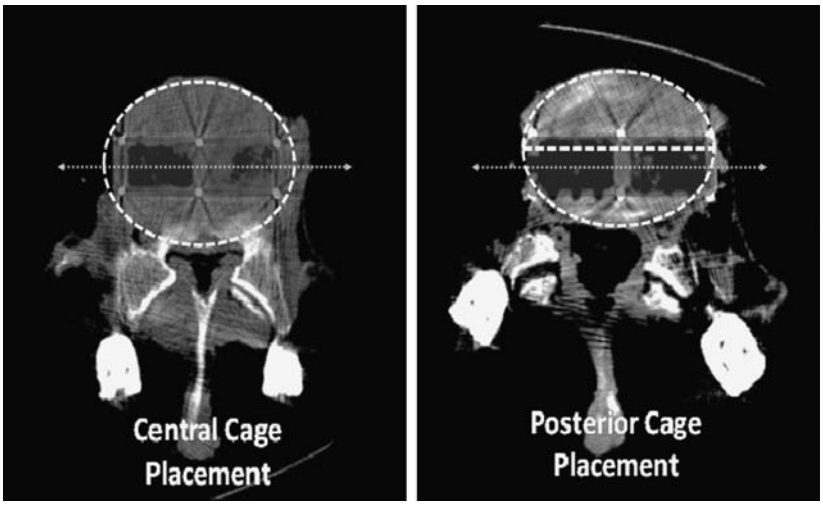

FIGURE 3. Axial computed tomography images illustrating the central (left) and posterior (right) interbody cage position techniques employed in this study. Thin horizontal dotted lines indicate axis of symmetry for the extreme lateral interbody fusion cage. Thick horizontal dashed lines indicate central axis of symmetry for the vertebral body endplate.

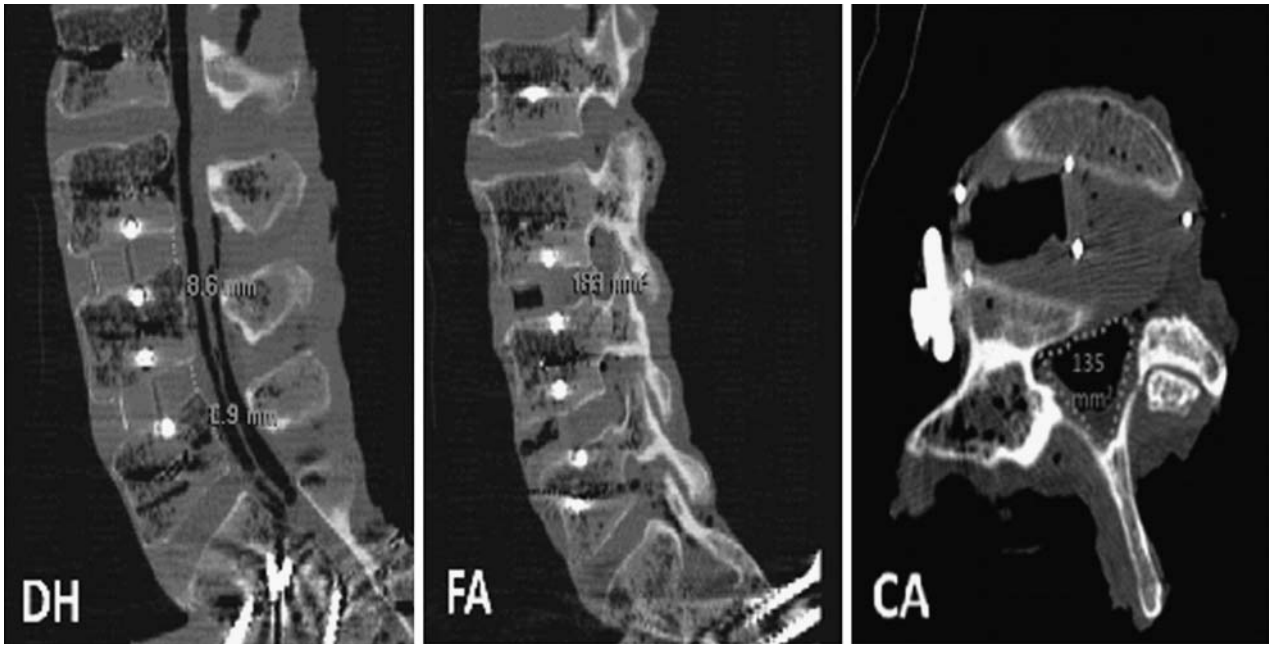

FIGURE 4. Sagittal computed tomography images illustrating disk height (DH), foraminal area (FA), and canal area (CA) measurements. DH measurements were made in the sagittal plane passing through the vertebral midline. CA was measured at the level of the disk for all instrumented levels.

($P < 0.001$) were also observed in the pedicle screw constructs with XLIF cages (Fig. 6).

Posterior pedicle screw/rod instrumentation afforded a significantly greater increase in posterior disk height ($P = 0.010$) and foraminal area ($P = 0.019$) compared to the lateral plate group. There was no significant difference between the increase in canal area afforded by XLIF cages and posterior bilateral pedicle screw/rods compared to XLIF cages and lateral plate/screws ($54.65 \pm 33.29\,mm^2$ and $49.60 \pm 37.10\,mm^2$, respectively, $P = 0.693$).

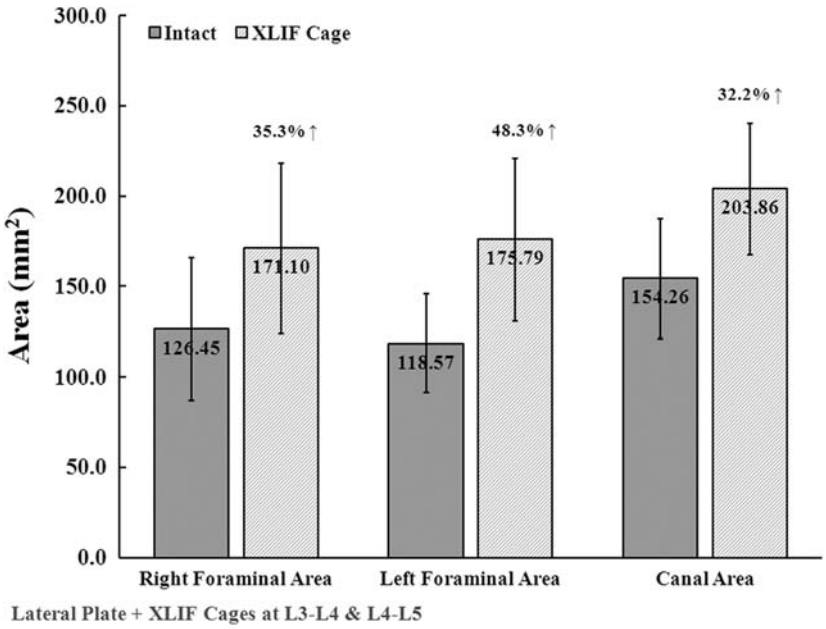

FIGURE 5. For the lateral plate + XLIF cage constructs, radiographic analysis indicated significant increases in all computed tomography–based measurements ($P \leq 0.002$). XLIF indicates extreme lateral interbody fusion.

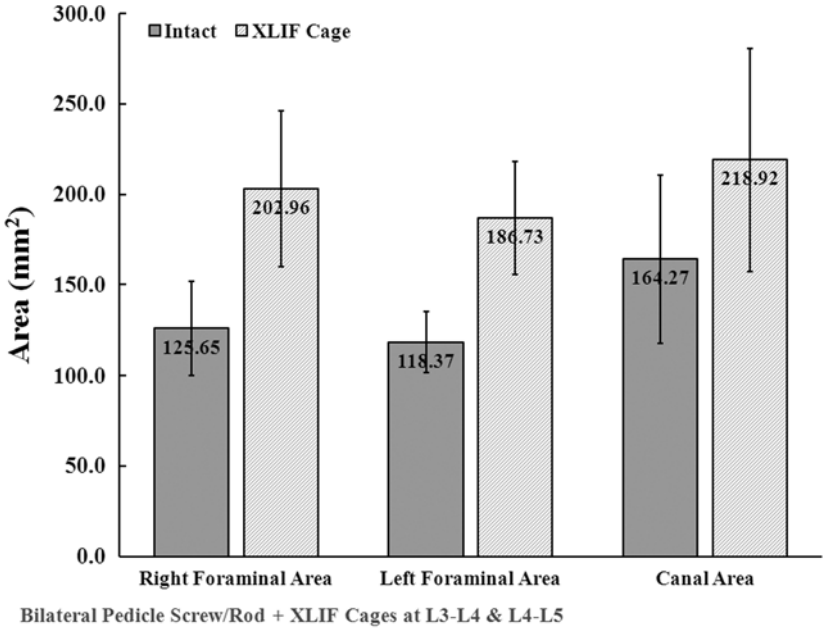

FIGURE 6. For the pedicle screw/rod + XLIF cage constructs radiographic analysis indicated significant increases in all computed tomography–based measurements ($P \leq 0.001$). XLIF indicates extreme lateral interbody fusion.

DISCUSSION

Lumbar stenosis is a pervasive cause of morbidity and disability in the adult population. Nonoperative treatment is often ineffective and patients ultimately require surgical decompression with or without spinal fusion. Continual advances in surgical techniques and instrumentation have allowed surgeons to explore new surgical approaches to obtain adequate neural decompression. For the past 2 decades, several authors have reported their experience with minimally invasive techniques for spinal decompression. Due to the high perioperative morbidity associated with spinal procedures,[1–4] it is of paramount importance to precisely confirm the proposed benefits of any new surgical technique.

The extreme lateral approach technique has been recently proposed as an effective surgical alternative to conventional anterior/posterior spine surgery to obtain decompression of the neural elements and alleviate pain.[6–8,12] Early clinical[11] and biomechanical[14] studies support the feasibility of the approach at affording indirect decompression in patients with neurological symptoms subsequent to instability and malalignment, while affording range of motion reductions that restore stability to the affected segment. The radiographic results reported here using a cadaveric model instrumented with a laterally placed interbody cage and supplementary lateral and posterior instrumentation provide further evidence in support of the clinical reports and add validity to the underlying rationale described for the minimally invasive technique.

One of the primary study goals was to elucidate the effect of lateral interbody cage placement within the interbody space on radiographic metrics consistent with indirect decompression. Study results derived from the L3–L4 and L4–L5 index levels indicate that increases in disk height, foraminal area, and canal area were not dependent on cage placement within the disk space (central vs. posterior). As intraoperative placement of a cage in the central portion of the disk is an easier and safer technique and also requires less operative time compared to posterior cage placement, our results suggest that central placement may be preferable in a clinical setting since sacrifices in quality of indirect decompression were not evident. The case for central cage placement is further supported by the kinematic results of a study run in parallel to that reported here which indicated that reduction in range of motion relative to the intact condition at the L3–L4 and L4–L5 levels was not a function of central or posterior interbody cage placement in the same cohort of cadaveric lateral plate and pedicle screw/rod lumbar fusion constructs.[15]

As previously mentioned, the implantation of the lateral cages affords the potential advantage of indirect decompression of the spinal canal thereby avoiding the need for an open or direct (laminectomy) surgical intervention.[7,10,11] The results of our study indicate that posterior disk height is significantly increased after appropriate sizing and cage insertion into the L3–L4 and L4–L5 disk spaces. Specifically, disk height was increased by 31% and 60% in the lateral plate and pedicle screw fusion constructs, respectively. Accompanying increases in disk height in both constructs were significant increases in foraminal area (lateral plate: 35.3%–48.3%; pedicle screw: 57.8%–61.5%) and canal area (lateral plate: 32.2%; pedicle screw: 33.3%). Our radiographic findings using a cadaveric model are in good agreement with the clinical findings of Oliveira et al[11]

who performed a prospective, nonrandomized clinical study on the decompressive effect of the minimally invasive procedure in 7 male and 14 female patients who underwent the minimally invasive technique. In their study, a total of 43 lumbar levels were studied in the patient cohort who suffered from symptomatic lumbar degenerative conditions with central and/or lateral stenosis. Compared to baseline lateral radiograph and axial MRI measurements, increases of 41.9%, 24.5%, and 33.1% were reported for disk height, foraminal area, and central canal area at the affected level immediately after stand-alone interbody cage insertion without additional direct posterior decompression or internal fixation. Our findings in a cadaveric model further support the role of these cage in ligamentotaxis and restoration of disk height with concomitant increases in lateral recess and central canal areas.

In comparing the radiographic outcome measures between the 2 instrumented fusion constructs, we identified a significant increase in both posterior disk height as well as foraminal area in the 2-level constructs with posterior screw/rod instrumentation. This finding may suggest that indirect decompression of the spinal cord could be improved in vivo in the acute term in such fusion constructs. There are 2 possible explanations for this finding. The first may very well be that the increased rigidity of the posteriorly instrumented constructs better maintains the initial indirect decompression afforded by the cages under the compressive preloads that were simulated by application of 400 N preload to all constructs before CT scanning in the current study. The second explanation may relate to the heterogenous cadaveric population in which we studied the effects of lateral cage implantation on indirect decompression in the lateral recess and central canal areas. Though the level of initial degeneration of all disks at the L3–L4 and L4–L5 levels was not quantified, the average baseline posterior disk height in the spines allocated for pedicle screw augmentation (5.6 mm) was 1.2 mm less than the average for the spines allocated for lateral plate augmentation (6.8 mm). Assuming that comparable levels of disk distraction were achieved during cage implantation, the relative increase in disk height in the pedicle screw group may be artificially inflated. Thus, the lack of homogeneity between groups with regard to baseline disk height may have resulted in the statistically significant increases in disk height and foraminal area relative to the lateral plate group. Therefore, based on the nature of our experimental design, this finding should be interpreted cautiously until clinical data arises that may help to better define supportive roles (with regard to maintenance of indirect decompression afforded by these cages) of additional instrumentation in lumbar fusion constructs.

The authors acknowledge several limitations with the present study. As with any cadaveric analysis, patient variables and in vivo anatomic structures have a particular biological response to trauma/surgery and are impossible to replicate in the laboratory. Further, the clinical correlation of the mathematical change in areas and lengths reported in this study is unknown and the use of a cadaveric model permits only the report of the acute increases in neural foramina dimensions through interbody distraction with the laterally placed cages. Clinical studies with long-term follow-up in patients receiving these interbody devices will only be able to accurately determine maintenance of correction and the lasting clinical benefit of the lateral approach technique. Finally, attention was given to selecting only cadaveric spines without any history of previous surgical interventions. However, specimen related characteristics such as integrity of the ALL, bone quality, pedicle size and morphology, and history of back pain or nerve compression symptoms of the donor may affect the overall results of the study. Also, it is understood that none of the specimens showed degenerative changes resulting into spontaneous facet joint fusion. Fused facet joints are contraindicative for indirect decompression procedures.

In summary, the authors believe that the present study helps to provide preliminary scientific support to the clinical use of the surgical technique. Our findings of significantly increased disk height, foraminal area, and canal area afforded by lateral cage implantation into cadaveric spines support the rationale for the minimally invasive technique at promoting indirect decompression of the spinal canal. Finally, the radiographic findings from this study provide in vitro evidence that the lateral approach technique is a viable alternative to open surgical intervention (laminectomy).

ACKNOWLEDGMENTS

The authors thank Sergio Gutierrez, PhD, Andres Cabezas, BS, and Karen Mann, BS for their assistance with specimen preparation and CT scanning.

REFERENCES

1. Airaksinen O, Herno A, Turunen V, et al. Surgical outcome of 438 patients treated surgically for lumbar spinal stenosis. *Spine (Phila Pa 1976)*. 1997;22:2278–2282.
2. Kou J, Fischgrund J, Biddinger A, et al. Risk factors for spinal epidural hematoma after spinal surgery. *Spine (Phila Pa 1976)*. 2002;27:1670–1673.
3. Potter BK, Freedman BA, Verwiebe EG, et al. Transforaminal lumbar interbody fusion: clinical and radiographic results and complications in 100 consecutive patients. *J Spinal Disord Tech*. 2005;18:337–346.
4. Villavicencio AT, Burneikiene S, Bulsara KR, et al. Perioperative complications in transforaminal lumbar interbody fusion versus anterior-posterior reconstruction for lumbar disc degeneration and instability. *J Spinal Disord Tech*. 2006;19:92–97.
5. Mardjetko SM, Connolly PJ, Shott S. Degenerative lumbar spondylolisthesis. A meta-analysis of literature 1970-1993. *Spine (Phila Pa 1976)*. 1994;19:2256S–2265S.
6. Madhok R, Kanter AS. Extreme-lateral, minimally invasive, transpsoas approach for the treatment of far-lateral lumbar disc herniation. *J Neurosurg Spine*. 2010;12:347–350.
7. Ozgur BM, Aryan HE, Pimenta L, et al. Extreme Lateral Interbody Fusion (XLIF): a novel surgical technique for anterior lumbar interbody fusion. *Spine J*. 2006;6:435–443.
8. Shen FH, Samartzis D, Khanna AJ, et al. Minimally invasive techniques for lumbar interbody fusions. *Orthop Clin North Am*. 2007;38:373–386. abstract vi.
9. Billiinghurst J, Akbarnia BA. Extreme lateral interbody fusion—XLIF. *Curr Orthop Pract*. 2009;20:238–251.

10. Pimenta L, Schaffa TL. Surgical technique: extreme lateral interbody fusion. In: Goodrich JA, Volcan IJ, eds. *eXtreme Lateral Interbody Fusion (XLIF)*. St. Louis, MO: Quality Medical Publishing; 2008:87–104.
11. Oliveira L, Marchi L, Coutinho E, et al. A radiographic assessment of the ability of the extreme lateral interbody fusion procedure to indirectly decompress the neural elements. *Spine (Phila Pa 1976)*. 2010;35:S331–S337.
12. Cornwall GB, Turner AW, Fogel GR, et al. Biomechanical analysis and review of lateral lumbar fusion constructs. *Spine (Phila Pa 1976)*. 2010;35:S361–S367.
13. Patwardhan AG, Havey RM, Meade KP, et al. A follower load increases the load-carrying capacity of the lumbar spine in compression. *Spine (Phila Pa 1976)*. 1999;24:1003–1009.
14. Nayak A, Cabezas A, Santoni BG, et al. Kinematic comparison of lateral plate versus pedicle screw construct in lumbar spine instrumented with lateral cage at two levels. *North American Spine Society's 26th Annual Meeting*, 2011, Chicago, IL.
15. Dakwar E, Cardona RF, Smith DA, et al. Early outcomes and safety of the minimally invasive, lateral retroperitoneal transpsoas approach for adult degenerative scoliosis. *Neurosurg Focus*. 2010;28:E8.

