

# Minimally Invasive Lateral Retroperitoneal Corpectomy for Treatment of Focal Thoracolumbar Kyphotic Deformity: Case Report and Review of the Literature

Rory J. Petteys<sup>1</sup> Faheem A. Sandhu<sup>1</sup>

<sup>1</sup> Department of Neurosurgery, Georgetown University Hospital, Washington, District of Columbia, USA

J Neurol Surg A

**Address for correspondence** Faheem A. Sandhu, MD, PhD, Department of Neurosurgery, Georgetown University Hospital, PHC-7, 3800 Reservoir Road NW, Washington, DC 20007, USA (e-mail: fasandhu@aol.com).

## Abstract

**Background** Corpectomy is a frequently performed procedure for pathologies of the anterior spine including neoplasms, fractures, deformities, and osteomyelitis. Traditional approaches to the anterior thoracic spine and thoracolumbar junction are associated with significant perioperative pulmonary complications and morbidity. Posterior and posterolateral approaches minimize some of these complications but are somewhat limited in visualization of the anterior elements.

**Patient and Methods** Here we report the case of a 49-year-old man with a remote thoracolumbar fracture and subsequent focal deformity treated with a minimally invasive lateral retroperitoneal corpectomy and open posterior arthrodesis.

**Conclusion** Minimally invasive lateral corpectomy is a safe and effective option for deformity correction. We discuss the relative advantages and disadvantages of this approach and review the relevant literature.

## Keywords

- minimally invasive
- trauma
- spinal fusion

## Introduction

Corpectomy is a commonly performed procedure for pathologic entities of the anterior thoracic and thoracolumbar vertebral column. These include metastatic or primary tumors, traumatic and pathologic fractures, deformity, and osteomyelitis causing spinal cord compression, deformity, or instability. The anterior spine can be accessed through several surgical approaches, including posterior, lateral extracavitary, antero-lateral, and direct anterior (transthoracic). The level(s) involved, the type of pathology, the patient's condition, and surgeon preference will all affect operative decision making.

These approaches are associated with different advantages and disadvantages. Anterior approaches provide superior visualization of the vertebral bodies and spinal canal to ensure complete decompression but are associated with significant pulmonary complications in 12% of patients.<sup>1</sup>

Thoracoscopic procedures can help reduce some of these complications but are also associated with significant pulmonary morbidity.<sup>2</sup> Posterior and posterolateral techniques, such as the lateral extracavitary approach (LEC), avoid the significant morbidity associated with transthoracic and transabdominal approaches to the spine while allowing good exposure for decompression, corpectomy, and reconstruction. However, the LEC approach is associated with extensive muscle dissection and blood loss.<sup>3</sup>

Recent technological developments in minimally invasive spine surgery have led to an increasing number of spine procedures being performed with these techniques. Minimally invasive techniques minimize tissue dissection and damage and reduce blood loss. Here, we report the case of a 49-year-old man with a remote L1 vertebral body fracture and subsequent kyphotic deformity treated with a minimally invasive lateral retroperitoneal corpectomy and open posterior arthrodesis.

received  
February 16, 2012  
accepted  
October 20, 2012

© Georg Thieme Verlag KG  
Stuttgart · New York

DOI <http://dx.doi.org/10.1055/s-0033-1334489>.  
ISSN 2193-6315.

## Case Presentation

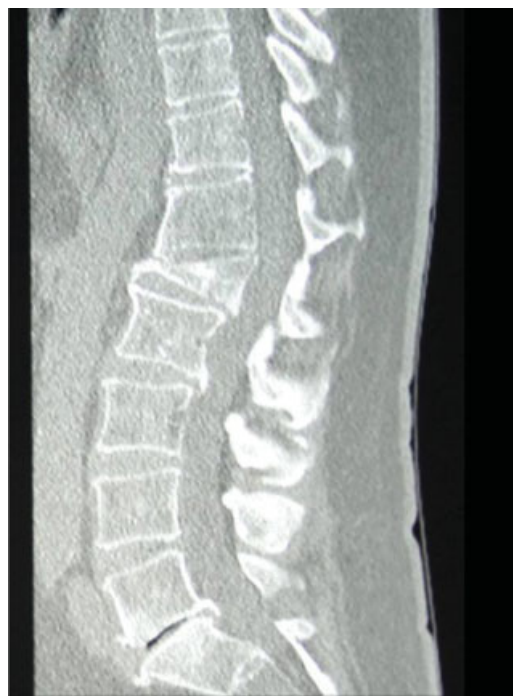A 49-year-old man who experienced a traumatic L1 vertebral body burst fracture 18 years previously during a motorcycle accident was treated conservatively at that time with bracing and bed rest. He initially did quite well and was pain free for several years. However, over the past 4 years, he developed progressive back pain resulting in limited mobility, decreased performance at work, and increasing narcotic use. Conservative measures (physical and injection therapy) initially offered some relief, but these treatments were no longer helpful. Injection therapy was helpful in localizing his pain to the thoracolumbar junction.

Upon presentation, he was noted to be in distress due to his back pain and he was unable to stand fully upright without pain. He denied weakness, pain, or paresthesias in his legs, and he denied any bowel or bladder dysfunction. Physical examination revealed an obese man (body mass index [BMI] 36.6) with full strength in all muscle groups, diminished sensation bilaterally in his groin, and hyperreflexia in both lower extremities. Preoperative magnetic resonance imaging (MRI) and sagittal computed tomography (CT) demonstrated a focal fixed kyphotic deformity of 15 degrees at the thoracolumbar junction with more than 50% loss of the L1 vertebral body height and 5 mm of retrolisthesis of T12 on L1 (→Figs. 1 and 2). Although he was well compensated for this focal deformity, his overall sagittal balance was shifted anteriorly by 2 cm. Additionally, the retrolisthesis and kyphotic deformity produced moderate stenosis of the spinal canal at T12 and L1.

## Surgical Technique

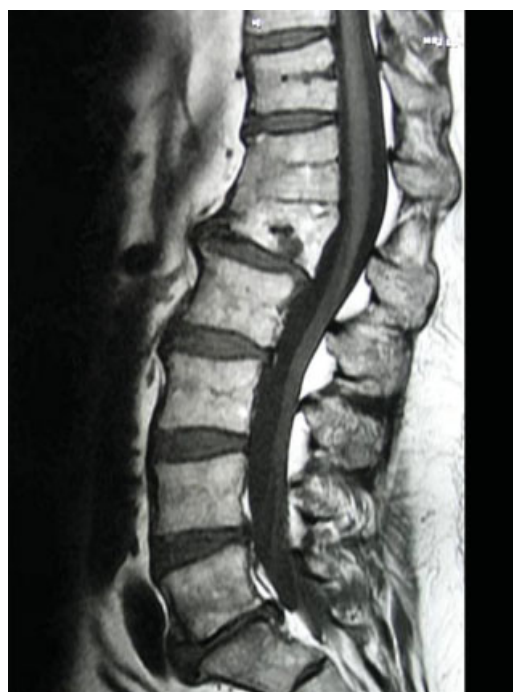Given the patient's obesity, the initial surgical plan was to perform the entire correction posteriorly via a modified lateral extracavitary approach. Pedicle screw instrumentation from T10 to L3, T12, and L1 laminectomies, and Smith-Peterson osteotomies, were performed. Excessive epidural bleeding was encountered due to the patient's body habitus, and the procedure was aborted without posterior fixation. Rods were not placed at this stage and the osteotomies were not closed. The plan for posterior corpectomy was then altered to include a second stage minimally invasive anterior L1 corpectomy and posterior arthrodesis and rod placement.

For the L1 corpectomy the patient was placed in the right lateral decubitus position and a 6-cm incision was made over the 11th rib directly above the L1 vertebral body. The rib was excised along the full extent of the incision, the parietal pleura entered, and blunt dissection performed below the diaphragm until the psoas muscle was clearly visualized. Serial dilators were passed through the psoas muscle approximately three quarters posteriorly on the L1–2 disc space using fluoroscopy and continuous electromyography (EMG) monitoring. The working retractor (MaxAccess, Nuvasive, San Diego, California, USA) was secured to the L1–2 disc space by a shim placed in the posterior blade. Following completion of the L1–2 discectomy, the retractor was turned slightly rostral and then opened fully to expose the T12–L1 disc space and

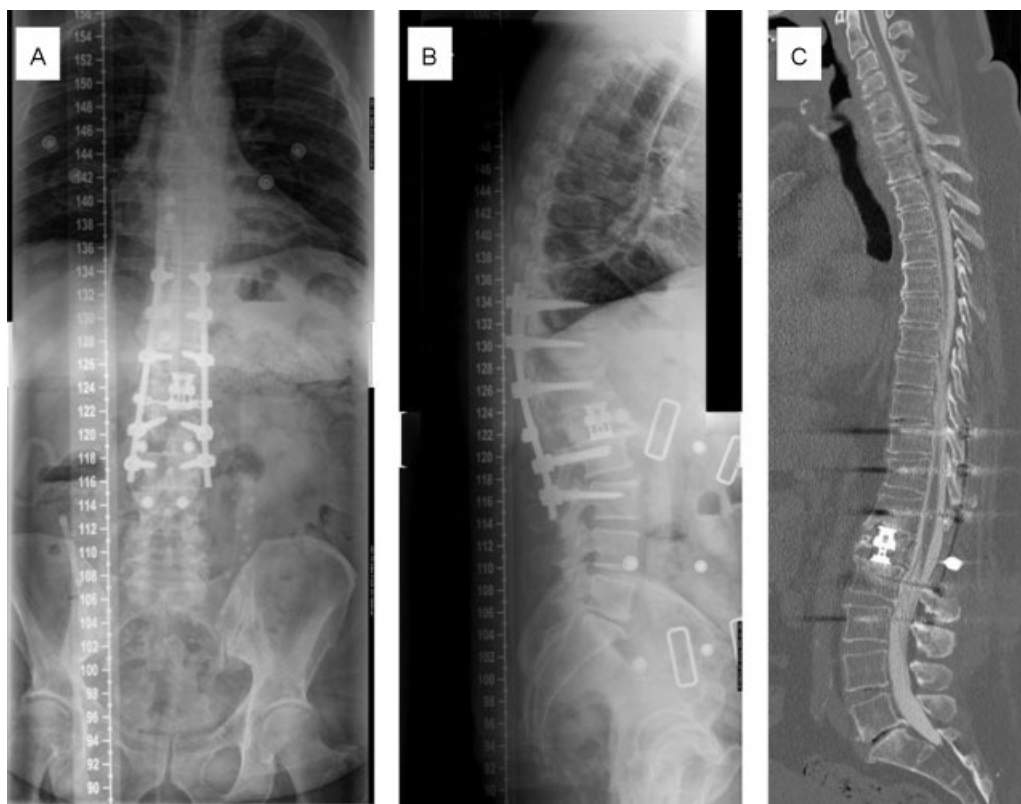


**Fig. 1** Preoperative sagittal computed tomography (CT) reconstruction demonstrating L1 vertebral body fracture and kyphotic deformity of 15 degrees.

the L1 vertebral body; the superior retractor blade was secured to the T12 vertebral body with another shim. Intraoperative somatosensory evoked potentials were monitored and the field was stimulated to ensure that lumbar nerve roots were clear of the field; the lumbar nerve roots were



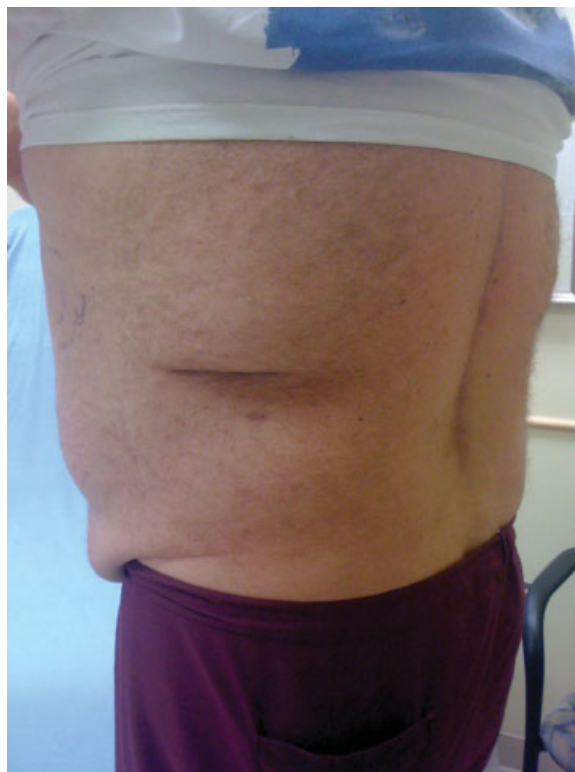**Fig. 2** Preoperative sagittal magnetic resonance imaging (MRI) demonstrating L1 vertebral body fracture, retrolisthesis, and anterior fusion mass.



**Fig. 3** Postoperative anterior-posterior (A) and lateral (B) radiographs demonstrating anterior interbody cage placement and posterior pedicle screw and rod arthrodesis. Postoperative computed tomography (CT) myelogram sagittal reconstruction (C) demonstrating decompression of the thecal sac and correction of kyphosis, now 2 degrees.

clearly posterior to the retractor and further dissection was not necessary. T12–L1 discectomy was then performed and the L1 segmental artery was identified and ligated. The partial L1 corpectomy was completed using osteotomes and a high-speed drill with bone saved for later use in arthrodesis. The anterior two thirds of the L1 vertebral body was removed with complete contralateral and anterior release. Additional removal of the vertebral body was not done since the posterior compression was not severe and adequate releases had been achieved. An 18-mm diameter distractible cage (VLIFT, Stryker, Kalamazoo, Michigan, USA) was packed with autograft bone, placed into the corpectomy defect, and fully expanded to 32 mm. Additional bone graft was then packed in and around the cage and the wound was closed in layers. A pediatric chest tube was placed in the pleural cavity prior to skin closure, suction was applied, and the chest tube was then removed. The skin was closed and the patient was turned prone for the posterior pedicle screw and rod arthrodesis.

Following the procedure, the patient did well and was discharged home on postoperative day 8. He reported decreased back pain and was able to return to work. One year following surgery, he rated his Visual Analog Scale (VAS) pain level as 3. Postoperative radiographs showed good placement of instrumentation and height restoration of the L1 vertebral body; the kyphosis angle was 2 degrees and the sagittal balance was normal (►Fig. 3). Additionally, his incisions healed well, and he was left with minimal scarring and without postthoracotomy pain (►Fig. 4).



**Fig. 4** Postoperative photograph of the patient's incisions. Note the small 6-cm incision used to access the anterior column.



## Discussion

Corpectomy is indicated for a variety of pathologies of the anterior vertebral column, including primary or metastatic tumors, traumatic or pathologic fractures, and bacterial or tuberculous osteomyelitis leading to spinal cord compression, intractable pain, or deformity. The thoracolumbar junction is particularly prone to fractures due to the unique biomechanical properties of the region. Conservative measures are often adequate treatment of these fractures, but some patients develop deformity or instability requiring surgical management.

The optimal surgical approach to the anterior vertebral column is determined by several factors, including levels affected, pathology involved, patient comorbid factors, and surgeon preference. Options for approach to the vertebral body include posterolateral, anterolateral, and direct anterior procedures.

Anterior and anterolateral approaches provide the best visibility and exposure of vertebral body pathology and permit direct visualization of the anterior spinal elements and the thecal sac. This ensures complete excision of the pathologic entity, thorough decompression of the spinal canal, and the ability to directly reconstruct the anterior spinal column. However, anterior approaches are associated with major complications in 12% of patients, including pulmonary contusion, atelectasis, pleural effusion, hemothorax, chylothorax, and significant postoperative pain.<sup>1,4</sup> Thoracoscopy is associated with fewer, but still significant, procedure-related pulmonary complications in 14 to 29% of patients.<sup>2,5</sup>

Posterior and posterolateral approaches were developed to avoid the complications of transthoracic surgery. The LEC eliminates the complications associated with transthoracic techniques and allows good access to decompress and reconstruct the anterior and posterior elements. The LEC has proven effective for the treatment of anterior spinal pathology<sup>3,6</sup> but is associated with substantial blood loss and postoperative pain due to the extensive muscle dissection.<sup>3</sup>

In recent years, minimally invasive approaches to the lumbar spine through tubular retractors have gained popularity. Several studies have demonstrated good clinical outcomes and deformity correction that are comparable to open techniques.<sup>7–9</sup> The potential advantages of these minimal access approaches include limited muscle dissection and retraction, smaller incisions, and less dead space, leading to reduced postoperative pain, increased mobility, and reduced infection rates. In the thoracic spine the perioperative morbidity of transthoracic approaches can be avoided. The lateral approach may also offer greater visibility of the vertebral body and anterior spinal cord than do posterolateral approaches, minimizing injuries to the spinal cord and thecal sac. Some drawbacks to the lateral approach include less-optimal visualization of the ventral spinal canal than direct anterior approaches and the risk of injury to the psoas muscle and lumbosacral nerve roots with associated postoperative weakness. There are several ways to address the psoas muscle, including dissecting it from its anterior attachments

and retracting posteriorly or using tubular dilators to directly traverse the muscle. Generally, mobilizing the psoas muscle from its anterior attachments is protective of the nerves that remain embedded in the muscle. In contrast, a transpsoas approach, as used in this case, requires the use of continuous EMG monitoring to safely navigate the lumbar plexus. Both techniques allow exposure of the ventral spinal canal. Although the exposure via a lateral approach using expandable tubular retractors can be limited and make multilevel exposures and complete corpectomies challenging, additional dissection and retractor adjustments can improve visualization and allow for complete corpectomy as well as spinal canal decompression.

Minimally invasive techniques have also been applied in the thoracic and thoracolumbar spine. However, few reports exist describing minimal-access approaches for corpectomy of the thoracic or lumbar spine. Kim et al have reported a clinical series of four patients and six cadavers, in which corpectomies were performed via a minimally invasive posterolateral approach through tubular retractors, an approach analogous to open costotransversectomy.<sup>10</sup> The patients treated included two with traumatic T6 vertebral body fractures, one with T4–5 plasmacytoma, and one with T12 colon cancer metastasis. The authors reported good ventral decompression of the spinal canal and placement of interbody grafts and instrumentation, along with good relief of back pain. Additionally, they reported no intraoperative neurologic injury or dural tears.

Here, we report a case of successful surgical treatment of an L1 vertebral body fracture with kyphotic deformity through a lateral minimal access approach. This was accomplished through a 6-cm incision, and though the parietal pleura was entered, the lack of lung retraction or violation of the visceral pleura permitted removal of a chest tube in the operating room prior to skin closure. The ability to minimize pulmonary complications while maximizing visualization of the vertebral body made the lateral approach well suited for treatment of the deformity in our patient. This permitted complete anterior column release and excellent correction of the deformity. If further decompression of the spinal cord was necessary, it could easily have been accomplished with additional posterior dissection and retractor adjustment using this approach.

## Conclusion

Corpectomy is a frequently performed procedure for pathology of the spine. Here, we have reported a minimally invasive lateral retroperitoneal corpectomy used to treat a fixed thoracolumbar kyphotic deformity. This is a promising approach that may reduce the perioperative morbidity of traditional transthoracic approaches. The lateral approach may also minimize intraoperative injuries to the spinal cord and thecal sac by affording greater anterior visibility than posterior approaches. This technique represents a promising approach for the management of pathologies of the anterior vertebral column.

**Conflict of Interest**

None

**References**

- 1 Faciszewski T, Winter RB, Lonstein JE, Denis F, Johnson L. The surgical and medical perioperative complications of anterior spinal fusion surgery in the thoracic and lumbar spine in adults. A review of 1223 procedures. *Spine* 1995;20:1592–1599
- 2 McAfee PC, Regan JR, Zdeblick T, et al. The incidence of complications in endoscopic anterior thoracolumbar spinal reconstructive surgery. A prospective multicenter study comprising the first 100 consecutive cases. *Spine* 1995;20:1624–1632
- 3 Resnick DK, Benzel EC. Lateral extracavitary approach for thoracic and thoracolumbar spine trauma: operative complications. *Neurosurgery* 1998;43:796–802, discussion 802–803
- 4 Fessler RG, Sturgill M. Review: complications of surgery for thoracic disc disease. *Surg Neurol* 1998;49:609–618
- 5 Rosenthal D, Marquardt G, Lorenz R, Nichtweiss M. Anterior decompression and stabilization using a microsurgical endoscopic technique for metastatic tumors of the thoracic spine. *J Neurosurg* 1996;84:565–572
- 6 Stillerman CB, Chen TC, Couldwell WT, Zhang W, Weiss MH. Experience in the surgical management of 82 symptomatic herniated thoracic discs and review of the literature. *J Neurosurg* 1998;88:623–633
- 7 Holly LT, Schwender JD, Rouben DP, Foley KT. Minimally invasive transforaminal lumbar interbody fusion: indications, technique, and complications. *Neurosurg Focus* 2006;20:E6
- 8 Khoo LT, Palmer S, Laich DT, Fessler RG. Minimally invasive percutaneous posterior lumbar interbody fusion. *Neurosurgery* 2002;51(5, Suppl):S166–S1
- 9 Park P, Foley KT. Minimally invasive transforaminal lumbar interbody fusion with reduction of spondylolisthesis: technique and outcomes after a minimum of 2 years' follow-up. *Neurosurg Focus* 2008;25:E16
- 10 Kim DH, O'Toole JE, Ogden AT, et al. Minimally invasive posterolateral thoracic corpectomy: cadaveric feasibility study and report of four clinical cases. *Neurosurgery* 2009;64:746–752, discussion 752–753