

# Effects on inadvertent endplate fracture following lateral cage placement on range of motion and indirect spine decompression in lumbar spine fusion constructs: A cadaveric study

Brandon G. Santoni, PhD<sup>a</sup>, Gerald E. Alexander III, MD<sup>b</sup>, Aniruddh Nayak, MS<sup>a</sup>,  
Andres Cabezas, BS<sup>a</sup>, German A. Marulanda, MD<sup>b</sup>, Ryan Murtagh, MD<sup>c</sup>,  
Antonio E. Castellvi, MD<sup>d,\*</sup>

<sup>a</sup> Phillip Spiegel Orthopaedic Research Laboratory, Foundation for Orthopaedic Research & Education, Tampa, FL

<sup>b</sup> Department of Orthopaedics & Sports Medicine, University of South Florida, Tampa, FL

<sup>c</sup> University Diagnostic Institute, Tampa, FL

<sup>d</sup> Center for Spinal Disorders, Florida Orthopaedic Institute, Tampa, FL

## Abstract

**Background:** The lateral transposas approach to interbody fusion is gaining popularity. Existing literature suggests that perioperative vertebra-related complications include endplate breach owing to aggressive endplate preparation and poor bone quality. The acute effects of cage subsidence on stabilization and indirect decompression at the affected level are unknown. The purpose of this study was to compare the kinematics and radiographic metrics of indirect decompression in lumbar spines instrumented with laterally placed cages in the presence of inadvertent endplate fracture, which was determined radiographically, to specimens instrumented with lateral cages with intact endplates.

**Methods:** Five levels in 5 specimens sustained endplate fracture during lateral cage implantation followed by supplementary fixation (pedicle screw/rod [PSR]: n = 1; anterolateral plate [ALP]: n = 4), as part of a larger laboratory-based study. Range of motion (ROM) in these specimens was compared with 13 instrumented specimens with intact endplates. All specimens were scanned using computed tomography (CT) in the intact, noninstrumented condition and after 2-level cage placement with internal fixation under a 400-N follower load. Changes in disc height, foraminal area, and canal area were measured and compared between specimens with intact endplates and fractured endplates.

**Results:** Subsidence in the single PSR specimen and 4 ALP specimens was 6.5 mm and  $4.3 \pm 2.7$  mm (range: 2.2–8.3 mm), respectively. ROM was increased in the PSR and ALP specimens with endplate fracture when compared with instrumented specimens with intact endplates. In 3 ALP specimens with endplate fracture, ROM in some motion planes increased relative to the intact, noninstrumented spine. These increases in ROM were paralleled by increase in cage translations during cyclic loading (up to 3.3 mm) and an unpredictable radiographic outcome with increases or decreases in posterior disc height, foraminal area, and canal area when compared with instrumented specimens with intact endplates.

**Conclusions:** Endplate fracture and cage subsidence noted radiographically intraoperatively or in the early postoperative period may be indicative of biomechanical instability at the affected level concomitant with a lack of neurologic decompression, which may require revision surgery.

© 2013 ISASS – The International Society for the Advancement of Spine Surgery. Published by Elsevier Inc. All rights reserved.

**Keywords:** Lumbar interbody fusion; Lateral transposas approach; Endplate fracture; Indirect decompression; Stability

## Introduction

Segmental stabilization and spine fusion may be a necessary adjunct to neurologic decompression in the degenerated spine. According to a 2005 study,<sup>1</sup> fusion procedures in the US represented > 50% of all lumbar spine operations excluding those for disc herniation. The same study reported

This study was supported by a research grant from NuVasive, Inc. (San Diego, CA).

\* Corresponding author: Antonio E. Castellvi, MD, Florida Orthopaedic Institute, Tampa, FL 33632; Tel./fax: +1-813-978-9700.

E-mail address: [doctorbackbone@aol.com](mailto:doctorbackbone@aol.com)

that the number of lumbar fusions increased 230% among patients 60 years and older from 1988–2001. Increases in fusion surgery were also apparent in patients in their 40s and 50s (180%) and 20s and 30s (120%). These data, along with the increasing size of the elderly population,<sup>2,3</sup> suggest that interbody fusion will continue to be a mainstay surgical intervention for alleviation of neurologic symptoms secondary to degenerative spine conditions.<sup>4</sup>

Traditionally, fusion has been accomplished via open approaches<sup>5</sup> that include anterior lumbar interbody fusion (ALIF),<sup>6,7</sup> posterior lumbar interbody fusion,<sup>8</sup> and transforaminal lumbar interbody fusion.<sup>9,10</sup> Complications associated with open spine fusion procedures have been described and include infection, visceral injury, instrumentation malposition, and neurologic deficits.<sup>5,6,9–13</sup> To mitigate these morbidities, minimally invasive surgical (MIS) approaches have been described, and include endoscopic ALIF,<sup>14</sup> mini-ALIF,<sup>15</sup> and MIS transforaminal lumbar interbody fusion.<sup>9</sup> The minimally invasive retroperitoneal transposas approach has been recently introduced and is gaining popularity. By virtue of the approach, an access surgeon is not necessary, and the need to mobilize the great vessels is obviated, which minimizes the potential for visceral and vascular complications. This advantage has been realized, with a recent clinical report of a zero incidence of intraoperative visceral injury.<sup>16</sup> Biomechanically, the technique allows a large discectomy and placement of a large interbody spacer that spans the dense apophyseal ring, promoting a large surface area for fusion. Authors in favor of the technique report that disc height (DH) restoration and correction of alignment can be better achieved through the ligamentotaxis allowed by intact anterior and posterior longitudinal ligaments.<sup>17,18</sup>

Clinical, radiographic, and biomechanical studies evaluating this technique have reported promising results regarding indirect decompression in patients while conferring stability to the affected segment(s).<sup>17,19</sup> Despite these findings, complication reports are minimal.<sup>20–23</sup> Rodgers et al.<sup>16</sup> reported an overall complication rate of 6.2% (37/600), with 6 vertebra-related complications including endplate fracture and vertebral

fracture/subsidence. To our knowledge, the acute effects of endplate breach and cage subsidence on biomechanical stability and indirect decompression at the affected level are unknown. The purpose of this study was to report the kinematic and radiographic effects of 5 endplate fractures sustained during placement of the interbody device and documented on postinstrumentation radiographs and computed tomography (CT) scans as part of larger biomechanical and radiographic study in human cadaveric lumbar spines.

## Materials and methods

### Endplate fracture specimens

A total of 36 L3-L4 (n = 18) and L4-L5 (n = 18) lumbar levels were instrumented with 18-mm wide cages (CoRoent XL; NuVasive Inc., San Diego, California) in 18 (n = 18) human cadaveric spines. Lateral discectomy was performed to remove sufficient disc material and prepare the vertebral endplates similar to clinical practice. The cages were made from polyetheretherketone, and the lateral length and height dimensions were determined by anatomy. The anterior and posterior longitudinal ligaments and anterior annulus were left intact, such that when the large footprint cage was inserted into the disc, the ligaments stretched owing to distraction. A total of 9 (n = 9) spines were randomly allocated to receive (1) lateral plate (XLP Plate; NuVasive) at each level or (2) bilateral pedicle screws (SpheRx and DBR II; NuVasive) at each level. Lateral plate and posterior pedicle screw/rod (PSR) instrumentation was facilitated with fluoroscopy and all procedures were performed by board-certified spine surgeons experienced with the lateral approach technique.

Of the n = 36 implanted lumbar levels, 5 (n = 5; 13.9%) levels in 5 specimens sustained inadvertent endplate fracture and apophyseal ring violation (Fig. 1) during cage placement (inferior: n = 4, 80%; superior: n = 1, 20%) as documented via lateral radiographs. Fracture occurred in 1 specimen in the PSR group and in 4 anterolateral plate (ALP) specimens. The 5 specimens were harvested from 2

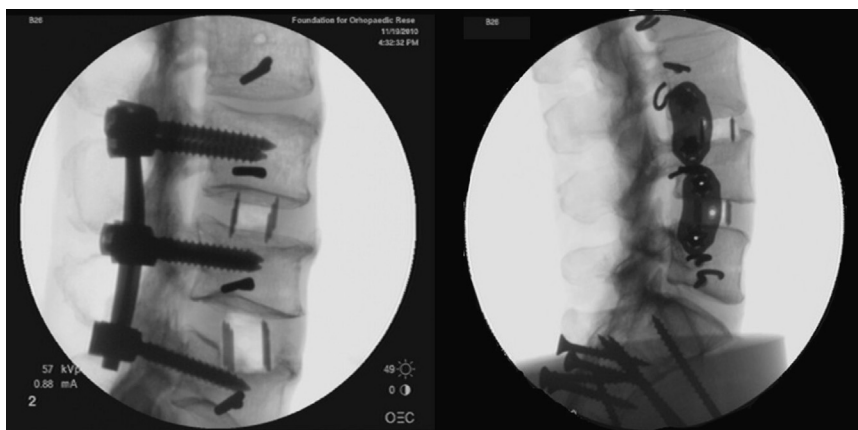


Fig. 1. Radiographic representative images of 2 endplate fractures sustained during lateral interbody cage implantation.

men and 3 women (average age: 61.4 years; range, 44–69). Bone mineral density of these specimens was assessed by dual energy X-ray absorptiometry (Lunar Prodigy; GE Healthcare, Madison, Wisconsin), with an average value of  $0.91 \pm 0.20 \text{ g/cm}^2$  (range: 0.81–1.01  $\text{g/cm}^2$ ) and an average T-score of  $-1.5$  (range: 2.4 to  $-3.5$ ) (Table 1). Measurements of cage subsidence into the vertebral body were performed on lateral radiographs of the specimens using Image J (the NIH, Bethesda, Maryland). Despite endplate fracture, the specimens were subjected to the same biomechanical and radiographical outcome measures as the remaining 13 specimens. The range of motion (ROM) and anatomical changes in DH, foraminal area (FA), and canal area (CA) quantified in the 5 instrumented lumbar levels with endplate fracture were compared with the instrumented levels with intact endplates in the PSR ( $n = 17$  levels) and ALP ( $n = 14$  levels) groups in our post hoc analysis.

#### Kinematic analysis and measurement of interbody cage motion

Pure moment flexibility testing was performed in accordance with our prior methods (Fig. 2A),<sup>24,25</sup> applying unconstrained moments of  $\pm 7.5 \text{ N-m}$  in flexion-extension (F/E), right and left lateral bending (LB), and axial rotation (AR). Applied moments were maintained for 10 seconds before recording ROM. Specimens were cycled 3 times before the beginning of each loading mode and motion segment kinematics were obtained using an optoelectronic motion analysis system (Optotrak Certus; Northern Digital Inc., Waterloo, Ontario, Canada).

After kinematic evaluation, the specimens were mounted in a biaxial TestResources load frame (Model 800L, Shakopee, Minneapolis) and coupled to custom-designed fixtures that cycled the specimens in F/E (4 N-m, with 400 N preload), LB (2 N-m) and AR (5 N-m) for 500 cycles at 0.5 Hz. Assuming the polyetheretherketone cages to be rigid bodies, custom-designed marker flags (Fig. 2B) were coupled to the cages at the index levels using threaded screws to quantify cage translations during cyclic loading in the anterior-posterior, medial-lateral, and inferior-superior directions.<sup>25</sup> Briefly, threaded holes were created in cages where

access to prethreaded holes was obstructed (as with the lateral plates). The translations for each cage were measured relative to the superior vertebral body. Local coordinate systems were defined in the vertebral body and interbody cage by coupling optoelectronic marker triads to them. With the use of a digitizing pen, 2 points were defined on the right and left lateral aspects of the L3 and L4 inferior endplates at the vertebral body midline, which defined the + x axis. A single point was digitized on the anterior-most aspect of the body, defining the + z axis and, by default, the + y axis. Similarly, 3 points were digitized on the cage to define the interbody cage's local coordinate system. Thus, any translations measured along the x, y, and z axes during cyclic loading were defined as interbody cage translations in the disc space. Care was taken to digitize points such that the x-z planes were parallel to one another. The loading sequence was randomized for each specimen and the average peak-to-peak displacement amplitudes were derived from the last 10 cycles for each loading condition in the instrumented constructs.

#### Radiographic analysis

CT scans taken at 0.625-mm slice thickness (GE Lightspeed QX/i; GE Healthcare, Waukesha, Wisconsin) were taken of the specimens in the intact, noninstrumented condition and after cage implantation with supplementary fixation while under 400 N of compressive preload. The preload was applied to simulate the loads experienced by the lumbar spine in standing position and allow for the consequent reorientation of the spinal elements (disc/facet joints etc.) and neuroforaminal changes. This procedure of follower load application along the sagittal plane was in compliance with the technique proposed by Patwardhan et al.<sup>26</sup>

The CT scans were analyzed using 3D radiographic reconstruction software (Vitrea 2, ver. 3.5; Vital Images, Minnetonka, Minneapolis). Baseline (ie, intact) and post-interbody cage implantation posterior DH, right and left FA, and CA dimensions were measured in triplicate (Fig. 3) on a standardized radiology workstation. Radiographic parameters were measured independently by a fellowship-trained musculoskeletal radiologist. An orthopedic surgery resident

Table 1  
Bone quality, measured cage subsidence, and cage dimensions in levels with endplate fracture

	L1-L4 BMD ( $\text{g/cm}^2$ )	T-Score and WHO classification	Interbody cage subsidence (mm)			Cage height (mm)	Cage dimensions (w × l) (mm)
			Anterior	Posterior	Average		
Pedicle screw/rod							
Inferior endplate at L4-L5	0.901	-2.7 Osteoporotic	5.7	7.2	6.5	10	18 × 55
Lateral plate/screw							
<sup>A</sup> Inferior endplate at L3-L4	1.008	-1.5 Osteopenic	2.7	3.3	3.0	10	18 × 55
Inferior endplate at L3-L4	0.807	-3.5 Osteoporotic	5.7	10.9	8.3	12	18 × 55
Superior endplate at L4-L5	1.494	2.4 Normal	2.4	2.0	2.2	12	18 × 55
<sup>B</sup> Inferior endplate at L3-L4	0.939	-2.1 Osteopenic	3.4	4.0	3.7	10	18 × 55

Abbreviations: BMD, bone mineral density; WHO, World Health Organization.




Fig. 2. Test setup for pure moment (A) and cyclic (B) loading of the instrumented lumbar spine fusion constructs.

separately performed measurements of the CA only to acquire a general measure of interobserver reliability using this radiographic measurement technique. An interclass correlation coefficient and 95% CI were calculated to quantify the interobserver reliability and reported as a score between 0 (no agreement) and 1 (perfect agreement). Radiographic measurements were repeatable between observers. The interobserver reliability was excellent (interclass correlation coefficient = 0.986; 95% CI: 0.850–0.994).

**Results**

*Kinematic and radiographic analysis*

Interbody cage subsidence in the single PSR specimen measured 5.7 and 7.2 mm anteriorly and posteriorly, respectively (Table 1). Relative to the intact noninstrumented spine, ROM in F/E, LB, and AR ROM of the PSR-

instrumented L3-L4 and L4-L5 lumbar levels with intact endplates was reduced, on average, by  $85.4 \pm 4.4\%$ ,  $91.3 \pm 2.7\%$ , and  $64.0 \pm 10.6\%$ , respectively. In the single PSR specimen with endplate fracture, ROM was marginally reduced relative to the intact, noninstrumented spine in F/E, LB, and AR by 32.3%, 61.1%, and 19.5%, respectively (Table 2). Interbody cage translations during cyclic loading increased in the single PSR specimen with endplate fracture, particularly during AR loading with translations of up to 3.3 mm measured (Table 3). Over both levels, PSR constructs with intact endplates displayed, on average, 62.8%, 62.0%, and 34.5% increases in posterior DH, FA, and CA, respectively, relative to the intact, noninstrumented spine (Table 4). The endplate fracture PSR specimen demonstrated 38.1%, 37.5%, and 49.1% increases in the same radiographically measured indices of indirect decompression.

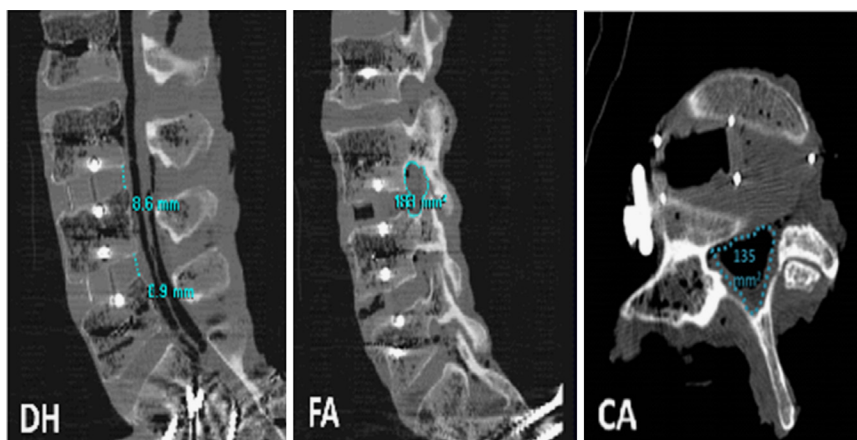


Fig. 3. Sagittal CT images illustrating posterior disc height (DH), foraminal area (FA), and canal area (CA) measurements. Disc height measurements were made in the sagittal plane. Canal area was measured at the level of the disc for all instrumented levels.



Table 2  
ROM results for specimens with endplate fracture subsequent to interbody cage implantation

Endplate fracture location and level	Range of motion (degree)								
	F/E			LB			AR		
	Intact	XLIF	Percentage reduction (%)	Intact	XLIF	Percentage reduction (%)	Intact	XLIF	Percentage reduction (%)
<b>Pedicle screw/rod</b>									
Inferior endplate at L4-L5	8.3	5.7	32.3	12.8	5.0	61.1	7.8	6.3	19.5
	*PSR group avg.			*PSR group avg.			*PSR group avg.		
	n = 17		85.4	n = 17		91.3	n = 17		64.0
	levels			levels			levels		
<b>Lateral plate/screw</b>									
<sup>A</sup> Inferior endplate at L3-L4	7.6	11.1	-45.7	7.5	13.4	-77.8	1.7	3.6	-111.6
Inertior endplate at L3-L4	11.1	9.1	17.5	11.4	12.9	-12.9	3.3	2.7	20.2
Superior endplate at L4-L5	16.5	15.6	5.8	19.5	8.8	54.7	5.1	7.2	-42.4
<sup>B</sup> Inferior endplate at L3-L4	9.8	5.5	44.5	15.5	7.1	54.1	8.6	3.6	58.0
Average	11.3	10.3	5.5	13.5	10.6	4.5	4.7	4.3	-19.0
	*ALP group avg.			*ALP group avg.			*ALP group avg.		
	n = 14		49.5	n = 14		67.3	n = 14		48.2
	levels			levels			levels		

Abbreviations: avg., average; XLIF, extreme lateral interbody fusion.

\*Average ROM for the respective treatments (PSR and ALP) in specimens with intact endplates.

Average interbody cage subsidence in the 4 ALP specimens was  $4.3 \pm 2.7$  mm (anterior range: 2.4–5.7 mm; posterior range: 2.0–10.9 mm). Relative to the intact noninstrumented spine, average ROM reductions of the instrumented L3-L4 and L4-L5 lumbar levels with intact endplates in the ALP group were  $49.5 \pm 21.9\%$ ,  $67.3 \pm 18.4\%$ , and  $48.2 \pm 14.7\%$  in F/E,

LB, and AR, respectively. In the 4 specimens with fractured endplates, ROM was reduced on average only by 5.5% and 4.5% in F/E and LB, respectively, relative to the intact noninstrumented spine. In AR, ROM was increased relative to the intact noninstrumented spine. A single instrumented specimen with an inferior endplate fracture at the L3-L4 level

Table 3  
Cage motion results for pedicle/screw rod and anterior-lateral plate specimens with endplate fracture during interbody cage placement

Endplate fracture location and level	Lateral cage translation (mm)								
	F/E			LB			AR		
	A-P	M-L	I-S	A-P	M-L	I-S	A-P	M-L	I-S
<b>Pedicle screw/rod</b>									
Inferior endplate at L4-L5	0.5	0.1	0.3	0.4	0.1	0.5	3.3	1.2	1.0
	*PSR group avg. (StDev)								
	n = 17 levels								
	0.4	0.1	0.2	0.2	0.1	0.2	0.8	0.3	0.2
	(0.1)	(0.1)	(0.1)	(0.1)	(0.1)	(0.2)	(0.4)	(0.3)	(0.1)
<b>Lateral plate/screw</b>									
<sup>A</sup> Inferior endplate at L3-L4	0.1	0.1	0.1	3.2	0.5	1.8	0.5	0.2	0.2
Inferior endplate at L4-L5	0.1	0.0	0.1	0.2	0.0	0.2	0.4	0.1	0.3
Superior endplate at L4-L5	0.3	0.1	0.7	0.4	0.8	2.1	2.1	1.5	0.5
<sup>B</sup> Inferior endplate at L3-L4	0.5	0.1	0.0	0.2	0.1	0.0	0.7	0.2	0.2
	*ALP group avg. (StDev)								
	n = 14 levels								
	0.3	0.1	0.2	0.2	0.2	0.2	0.8	0.2	0.4
	(0.2)	(0.1)	(0.4)	(0.1)	(0.4)	(0.2)	(1.0)	(0.3)	(0.4)

Abbreviations: avg., average; StDev, standard deviation. Lateral cage translations were measured during cyclic loading along the anterior-posterior (A-P), medial-lateral (M-L), and inferior-superior (I-S) axes for each loading mode.

\*Average cage translations for the respective treatments (PSR and ALP) in specimens with intact endplates.

Table 4

Radiographic indirect decompression results for pedicle screw/rod and anterior-lateral plate specimens with endplate fracture subsequent to lateral cage implantation

Endplate fracture location and level	Radiographic metric								
	Posterior disc height (DH, mm)			Foraminal area (FA, mm <sup>2</sup> )			Canal area (CA, mm <sup>2</sup> )		
	Intact	XLIF	Percentage increase (%)	Intact	XLIF	Percentage increase (%)	Intact	XLIF	Percentage increase (%)
<b>Pedicle screw/rod</b>									
Inferior endplate at L4-L5	7.0	9.7	38.1	112.0	154.0	37.5	108.0	161.0	49.1
	*PSR group avg.			*PSR group avg.			*PSR group avg.		
	n = 17 levels		61.8	n = 17 levels		62.0	n = 17 levels		34.5
<b>Lateral plate/screw</b>									
<sup>A</sup> Inferior endplate at L3-L4	6.0	4.0	-33.3	100.5	92.0	-8.5	177.0	183.0	3.4
Inertior endplate at L4-L5	5.0	7.0	40.0	117.5	170.0	44.7	162.5	205.5	26.5
Superior endplate at L4-L5	5.0	7.7	53.4	152.3	226.0	48.4	131.0	189.0	44.3
<sup>B</sup> Inferior endplate at L3-L4	8.0	13.0	62.5	119.5	193.0	61.5	128.0	173.5	35.5
	*ALP group avg.			*ALP group avg.			*ALP group avg.		
	n = 14 levels		37.6	n = 14 levels		43.4	n = 14 levels		38.1

Abbreviations: avg., average; XLIF, extreme lateral interbody fusion.

\*Average radiographic measures for the respective treatments (PSR and ALP) in specimens with intact endplates.

demonstrated increased ROM in all loading planes relative to the noninstrumented intact spine (Table 2). In this same specimen, interbody cage translations up to 3.2 mm were measured in LB (Table 3). Increases in cage translations were also quantified in the additional lateral plate specimens with endplate fracture. Averaged over both levels, ALP constructs with intact endplates displayed 37.6%, 43.4%, and 38.1% increases in posterior DH, FA, and CA, respectively, relative to the intact, noninstrumented condition (Table 4). Changes in the same radiographic measurements varied in the fractured ALP specimens. Posterior DH decreased by 33.3% in 1 specimen and increased by 62.5% in another. In the same 2 specimens, FA decreased by 8.5% and increased by 61.5%.

**Discussion**

Current literature supports lateral lumbar interbody fusion with the lateral approach technique as an alternative to open anterior or posterior approaches for spine fusion. Our review of the existing literature revealed that vertebral body fracture subsequent to intraoperative endplate breach is a complication associated with the technique<sup>16,20</sup> that may affect the quality of indirect decompression and require secondary procedures to alleviate persistent back pain.<sup>17,20</sup> Study results in 5 cadaveric spines with endplate breach provide supporting evidence that biomechanical stability and neural decompression may not be attainable with laterally placed interbody spacers even with additional lateral plate or posterior pedicle screw instrumentation.

The largest case series published to date describing perioperative complications in lateral interbody fusion is

by Rodgers et al.<sup>16</sup> In their retrospective analysis of 600 patients undergoing the minimally invasive procedure, the perioperative complication rate was 6.2%. Of the 37 documented complications in the patient cohort, 6 (1.0%) were vertebra related, with endplate fracture occurring in 1 patient and 1 case of vertebral body fracture/subsidence. Of the 6 vertebra-related complications, 5 required reoperation. In a smaller retrospective study of a surgeon’s early experience with the lateral approach, Dua et al.<sup>27</sup> and Kepler et al.<sup>28</sup> reported a high rate of vertebral body fracture, with 2 (15.4%) osteoporotic patients sustaining atraumatic coronal plane vertebral body fractures, one of which required kyphoplasty for repair. Further, a case series by Sharma et al.<sup>22</sup> reported that intraoperative endplate breach was a common intraoperative finding. In their study of 43 patients treated with the lateral approach with 1-year follow-up, intraoperative endplate breach occurred in 18 (20.7%) instrumented levels. The authors note, however, that endplate breach did not progress to vertebral fracture in most cases (only 2 documented) and did not affect fusion or alignment at the fusion level. Though there appears difficulty in assigning direct causality to endplate fracture with this approach, literature<sup>20,29</sup> cites factors such as aggressive endplate preparation and poor bone quality.

Though case series in small patient cohorts indicate that relief of back and leg pain is achievable with lateral interbody fusion, perioperative radiographic evidence of subsidence may result in inadequate resolution of stenotic symptoms as restoration of DH and alignment may be affected. In a radiographic study of stand-alone lateral interbody fusion in 43 lumbar levels, Oliveira et al.<sup>17</sup>

reported that the MIS procedure can confer the necessary decompression for treatment of central/lateral stenosis, with significant increases in DH (41.9%), FA (24.7%), and central canal diameter (33.1%). However, 2 patients did not experience alleviation of symptoms and it was noted radiographically that DH and foraminal height were not adequately restored. In 1 patient, postoperative radiographs indicated cage subsidence inferiorly with loss of sagittal correction. Revision surgery was performed and supplementary rigid posterior fixation was implanted. Our laboratory-based findings in 5 cadaveric specimens with subsidence support these clinical examples and suggest that neural decompression may not be achievable if endplate breach is radiographically identified. Further, our results indicate that segmental stability may also be adversely affected in the context of endplate breach.

As with the majority of other biomechanical studies on cadaveric specimens, our study shares some common limitations. Firstly, our results are only reported on a limited number of cadaveric specimens with endplate fracture ( $n = 5$ ), and thus the results presented herein may be best described as an experimental case study. Because of the small sample size, no statistical analysis was permitted to compare changes in ROM and radiographic metrics of indirect decompression between instrumented specimens with endplate fracture and those with intact endplates. Secondly, the results reported herein cannot take into account the biological changes that occur in vivo and therefore cannot be reasonably extrapolated to time periods beyond the immediate postoperative. Despite these limitations, there are a few points that warrant discussion. A total of 4 endplate fractures were identified in the ALP group providing us a small continuum in which to make generalities regarding subsidence and its effects on decompression, cage translation, and segmental rigidity. The 2 osteopenic specimens (denoted specimens A and B in Tables 1–4) demonstrated markedly different postinstrumentation kinematics, cage translations, and radiographic measures of indirect decompression. The latter may be attributable to markedly different changes in measured DH despite sustaining numerically similar amounts of interbody cage subsidence. In the preinstrumentation and postinstrumentation CT scans while under 400 N of compressive follower load, DH in specimen B increased from 8.0–13.0 mm (62.5% increase) after cage placement. This 5-mm increase in DH was paralleled by a 61.5% and 35.5% increase in FA and CA, respectively. All the 3 radiographic increases were greater than the average increase in the same parameters quantified in the  $n = 14$  instrumented lumbar levels with intact endplates. Further, cage translations in specimen B were numerically similar to instrumented spines with intact endplates. The biomechanical stability measured in this specimen was similar to the F/E, LB, and AR reductions in ROM quantified in the 14 instrumented levels with intact endplates. Conversely, posterior DH in specimen A decreased as a result of endplate fracture (intact,

noninstrumented level: 6.0 mm; lateral cage with endplate fracture: 4.0 mm). Resultantly, FA and CA were decreased (8.5%) and marginally increased (3.4%), respectively. In the same specimen, cage translations measured during LB were as great as 3.2 mm and ROM increased relative to the intact, noninstrumented spine in all 3 motion planes. DHs in the remaining 2 ALP specimens were increased by 2.0 and 2.7 mm with concomitant increases in FA (44.7% and 48.4%, respectively) and CA (26.5% and 44.3%, respectively). However, stability was not achieved in these specimens to the same level as those instrumented levels with intact endplates. This result may suggest that both biomechanical stability and neurologic decompression can be attainable with lateral fixation even if endplate breach is radiographically noted perioperatively as long as a relative increase in DH of 5 mm has been achieved via cage placement.

In summary, we identified 5 instances of endplate fracture in 5 cadaveric specimens instrumented with laterally placed interbody spacers and lateral plate or bilateral PSR fixation. In the presence of endplate fracture after cage placement, ROM was increased relative to instrumented specimens with intact endplates. Further, variable radiographic indices of indirect decompression were noted in these specimens with endplate fracture. Our controlled-laboratory study results suggest that stability and indirect decompression of the affected levels may not be attainable if endplate breach after lateral cage placement is noted radiographically.

## Acknowledgments

The authors would like to thank Andres Cabezas, BS, Karen Mann, BS, Rick Cain, MD, and Brian Dombly, MD for their assistance with specimen preparation and biomechanical testing.

## References

1. Deyo RA, Gray DT, Kreuter W, Mirza S, Martin BI. United States trends in lumbar fusion surgery for degenerative conditions. *Spine (Phila PA 1976)* 2005;30:1441–5; [discussion 6–7].
2. Anderson GF, Hussey PS. Population aging: A comparison among industrialized countries. *Health Aff (Millwood)* 2000;19:191–203.
3. US Census Bureau. US interim projections by age, sex, race and Hispanic origins, 2008. <http://www.census.gov/population/projections/files/methodology/idbsummeth.pdf>. Accessed February 6, 2012.
4. Rodgers WB, Gerber EJ, Rodgers JA. Lumbar fusion in octogenarians: The promise of minimally invasive surgery. *Spine (Phila PA 1976)* 2010;35:S355–60.
5. Kalanithi PS, Patil CG, Boakye M. National complication rates and disposition after posterior lumbar fusion for acquired spondylolisthesis. *Spine (Phila PA 1976)* 2009;34:1963–9.
6. Sasso RC, Best NM, Mummaneni PV, Reilly TM, Hussain SM. Analysis of operative complications in a series of 471 anterior lumbar interbody fusion procedures. *Spine (Phila PA 1976)* 2005;30:670–4.
7. Fantini GA, Pappou IP, Girardi FP, Sandhu HS, Cammisa Jr. FP. Major vascular injury during anterior lumbar spinal surgery: Incidence, risk factors, and management. *Spine (Phila PA 1976)* 2007;32:2751–8.

8. DiPaola CP, Molinari RW. Posterior lumbar interbody fusion. *J Am Acad Orthop Surg* 2008;16:130–9.
9. Park P, Foley KT. Minimally invasive transforaminal lumbar interbody fusion with reduction of spondylolisthesis: Technique and outcomes after a minimum of 2 years' follow-up. *Neurosurg Focus* 2008;25:E16.
10. Villavicencio AT, Burneikiene S, Bulsara KR, Thramann JJ. Perioperative complications in transforaminal lumbar interbody fusion versus anterior-posterior reconstruction for lumbar disc degeneration and instability. *J Spinal Disord Tech* 2006;19:92–7.
11. Carreon LY, Puno RM, Dimar 2nd JR, Glassman SD, Johnson JR. Perioperative complications of posterior lumbar decompression and arthrodesis in older adults. *J Bone Joint Surg Am* 2003;85-A:2089–92.
12. Kimura I, Shingu H, Murata M, Hashiguchi H. Lumbar posterolateral fusion alone or with transpedicular instrumentation in L4-L5 degenerative spondylolisthesis. *J Spinal Disord* 2001;14:301–10.
13. Scaduto AA, Gamradt SC, Yu WD, Huang J, Delamarter RB, Wang JC. Perioperative complications of threaded cylindrical lumbar interbody fusion devices: Anterior versus posterior approach. *J Spinal Disord Tech* 2003;16:502–7.
14. Bergey DL, Villavicencio AT, Goldstein T, Regan JJ. Endoscopic lateral transposas approach to the lumbar spine. *Spine (Phila PA 1976)* 2004;29:1681–8.
15. Kim JS, Kang BU, Lee SH, et al. Mini-transforaminal lumbar interbody fusion versus anterior lumbar interbody fusion augmented by percutaneous pedicle screw fixation: A comparison of surgical outcomes in adult low-grade isthmic spondylolisthesis. *J Spinal Disord Tech* 2009;22:114–21.
16. Rodgers WB, Gerber EJ, Patterson J. Intraoperative and early postoperative complications in extreme lateral interbody fusion. *Spine (Phila PA 1976)* 2010;36:26–33.
17. Oliveira L, Marchi L, Coutinho E, Pimenta L. A radiographic assessment of the ability of the extreme lateral interbody fusion procedure to indirectly decompress the neural elements. *Spine (Phila PA 1976)* 2010;35:S331–7.
18. Pimenta L, Schaffa TL. Surgical technique: Extreme lateral interbody fusion. In: Goodrich JA, Volcan IJ, editors. *eXtreme Lateral Interbody Fusion (XLIF)*. St. Louis, MO: Quality Medical Publishing; 2008. p. 87–104.
19. Cappuccino A, Cornwall GB, Turner AW, et al. Biomechanical analysis and review of lateral lumbar fusion constructs. *Spine (Phila PA 1976)* 2010;35:S361–7.
20. Brier-Jones JE, Palmer DK, Inceoglu S, Cheng WK. Vertebral body fractures after transposas interbody fusion procedures. *Spine J* 2011;11:1068–72.
21. Rodgers WB, Cox CS, Gerber EJ. Early complications of extreme lateral interbody fusion in the obese. *J Spinal Disord Tech* 2010;23:393–7.
22. Sharma AK, Kepler CK, Girardi FP, Cammisa FP, Huang RC, Sama AA. Lateral lumbar interbody fusion: clinical and radiographic outcomes at 1 year: A preliminary report. *J Spinal Disord Tech* 2011;24:242–50.
23. Youssef JA, McAfee PC, Patty CA, et al. Minimally invasive surgery: Lateral approach interbody fusion: Results and review. *Spine (Phila PA 1976)* 2010;35:S302–11.
24. Marulanda GA, Nayak A, Murtagh R, Santoni BG, Billys JB, Castellvi AEA. Cadaveric radiographic analysis on the effect of extreme lateral interbody fusion cage placement with supplementary internal fixation on indirect spine decompression. *J Spinal Disord Tech* (in press).
25. Nayak AN, Gutierrez S, Billys JB, Santoni BG, Castellvi AE. Biomechanics of lateral plate and pedicle screw constructs in lumbar spines instrumented at two levels with laterally placed interbody cages. *Spine J* (in press).
26. Patwardhan AG, Havey RM, Meade KP, Lee B, Dunlap B. A follower load increases the load-carrying capacity of the lumbar spine in compression. *Spine (Phila PA 1976)* 1999;24:1003–9.
27. Dua K, Kepler CK, Huang RC, Marchenko A. Vertebral body fracture after anterolateral instrumentation and interbody fusion in two osteoporotic patients. *Spine J* 2010;10:e11–5.
28. Kepler CK, Sharma AK, Huang RC. Lateral transposas interbody fusion (LTIF) with plate fixation and unilateral pedicle screws: A preliminary report. *J Spinal Disord Tech* 2011;24:363–7.
29. Lehman Jr. RA, Kang DG. Commentary: An increasing awareness of the complications after transposas lumbar interbody fusion procedure. *Spine J* 2011;11:1073–5.