

# Saphenous Nerve Somatosensory Evoked Potentials

*A Novel Technique to Monitor the Femoral Nerve During Transpoas Lumbar Lateral Interbody Fusion*

Justin Silverstein, MS, CNIM,\*† Laurence Mermelstein, MD,†‡ Hargovind DeWal, MD,†‡  
and Sushil Basra, MD†‡

**Study Design.** A retrospective analysis of a case series was performed.

**Objective.** To describe a novel technique to monitor femoral nerve function by analyzing the saphenous nerve somatosensory evoked potential (SSEP) during transpoas surgical exposures of the lumbar spine.

**Summary of Background Data.** During transpoas direct lateral approaches to the lumbar spine, electromyography monitoring is frequently advocated; however, sensory and motor neurological complications are still being reported. Femoral nerve injury remains a feared complication at the L3–L4 and L4–L5 levels. The current neurophysiological monitoring modalities are not specific or sensitive enough to predict these injuries after the retractors are placed. The authors have developed a technique that is hypothesized to reduce femoral nerve injuries caused by retractor compression by adding saphenous nerve SSEPs to their neurophysiological monitoring paradigm.

**Methods.** Institutional review board approval was granted for this study and the medical records along with the intraoperative monitoring reports from 41 consecutive transpoas lateral interbody fusion procedures were analyzed. The presence or absence of intraoperative changes to the saphenous nerve SSEP was noted and the postoperative symptoms and physical examination findings were noted.

**Results.** SSEP changes were noted in 5 of the 41 surgical procedures, with 3 of the patients waking up with a femoral nerve deficit. None of the patients with stable SSEP's developed sensory or motor deficits postoperatively. No patient in this series demonstrated intraoperative electromyography changes indicative of an intraoperative nerve injury.

From the \*Spine Medical Services, PLLC, Commack, NY; †Department of Orthopedics, NorthShore-LIJ Huntington Hospital, Huntington, NY; and ‡Long Island Spine Specialists, PC, Commack, NY.

Acknowledgment date: December 30, 2013. First revision date: February 3, 2014. Second revision date: March 20, 2014. Acceptance date: March 25, 2014.

The manuscript submitted does not contain information about medical device(s)/drug(s).

No funds were received in support of this work.

Relevant financial activities outside the submitted work: consultancy, stocks.

Address correspondence and reprint requests to Justin Silverstein, MS, CNIM, Director of Clinical Neurophysiology, Spine Medical Services, PLLC, 763 Larkfield Rd, Ste 202, Commack, NY 11725; E-mail: wiredneuro@gmail.com

DOI: 10.1097/BRS.0000000000000357

1254 www.spinejournal.com

**Conclusion.** Saphenous nerve SSEP monitoring may be a beneficial tool to detect femoral nerve injury related to transpoas direct lateral approaches to the lumbar spine.

**Key words:** femoral nerve, saphenous nerve, SSEP, lateral lumbar interbody fusion, transpoas lateral access surgery, femoral nerve injury, intraoperative neurophysiological monitoring, EMG, minimally invasive, triggered EMG.

**Level of Evidence:** 4

**Spine 2014;39:1254–1260**

Femoral nerve palsy is a feared neurological complication after transpoas lateral surgical exposures of the lumbar spine.<sup>1–3</sup> Touted as a less invasive surgical approach to the lumbar spine, most of the descriptions of this technique include the use of a special retractor designed to retract the retroperitoneal contents and the psoas muscle. Given the proximity of the lumbar plexus to this approach, various authors have described the use of intraoperative neurophysiological monitoring to improve the safety of this technique.<sup>1–5</sup> Current techniques for neurophysiological monitoring include triggered electromyography (t-EMG) and spontaneous electromyography (s-EMG); however, these modalities do not assess changes in nerve function caused by compression or ischemia and are limited in sensitivity and specificity.<sup>1,4–6</sup> Somatosensory evoked potentials (SSEPs) are sensitive to ischemic changes; however, current somatosensory techniques do not usually examine the femoral nerve and will not give any information, should the femoral nerve become ischemic.<sup>7–9</sup> The authors intend to present a novel neurophysiological monitoring technique that may reduce postoperative femoral nerve deficits. This article presents the use of saphenous nerve SSEPs to monitor for ischemic or compression injuries to the ipsilateral femoral nerve during a transpoas lateral interbody fusion.

## MATERIALS AND METHODS

Institutional review board approval was granted for this study and the medical records along with the intraoperative monitoring reports from 46 consecutive transpoas lateral interbody fusion procedures were analyzed. Five patients were omitted because of lack of obtaining the saphenous SSEP at baseline. Three fellowship-trained orthopedic spine surgeons

July 2014

performed lateral transpsoas interbody fusions on all patients and multimodal intraoperative neurophysiological monitoring with SSEP and EMG was employed.

A standard lateral approach was used for all surgical cases. The patients were positioned in a lateral decubitus position with care taken to pad all prominences, especially the dependent peroneal nerve area. The patients were secured to the operative table using wide surgical tape. The table was flexed to allow improved access to the surgical site. Fluoroscopic imaging was used to address the surgical levels. A single incision technique was utilized with a muscle splitting approach to the retroperitoneal space. Direct finger dissection of the retroperitoneum was used to sweep the peritoneal contents anteriorly. A blunt stimulator with continuous active EMG (triggered) stimulation was used to dissect through the psoas muscle to the lateral disc space. Sequential dilation over the initial probe was performed and a table mounted cylindrical retractor was placed. Direct stimulation of the tissue in the operative field was performed using a monopolar ball-tip probe and EMG responses were similarly recorded. t-EMG used a 5-ms/division time base, with a repetition rate of 5 Hz and a pulse width of 100 microseconds. A continuous constant current output was used starting at 0 mA and stopping at nerve depolarization up to 20 mA.

The investigators reviewed patient age, sex, preoperative diagnosis, intraoperative neurophysiological monitoring data, initial postoperative notes, first postoperative office visit and the 6- to 8-week postoperative office visit. Surgical levels were correlated to neurophysiological monitoring events and changes with the saphenous SSEP. Any change in the saphenous SSEP was cross checked with the patient's medical chart to identify true positive, false positive and presumed positive events. Any change in saphenous SSEP data also prompted review of EMG activity from femoral nerve innervated muscles. The medical charts from all 41 patients were reviewed to rule in/out any false-negative events.

### Intraoperative Neurophysiological Monitoring Methods

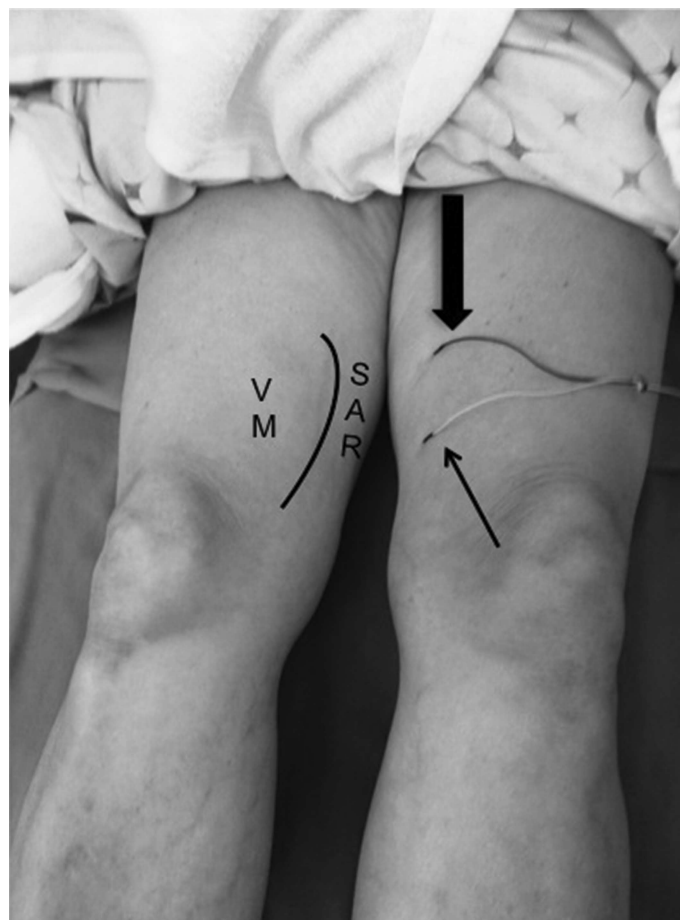
Saphenous nerve SSEPs were added to the traditional multimodality neurophysiological monitoring paradigm, which includes s-EMG, t-EMG, and SSEP. EMG was conducted in a standard fashion by placing subdermal needle electrodes in musculature associated with surgical levels being operated on (Table 1). SSEP monitoring was conducted from the ulnar and median nerves bilaterally in the upper extremities to monitor for positional induced injury. Deep peroneal and posterior tibial nerves were monitored from the lower extremities. A standard SSEP protocol was performed placing stimulating electrodes over the appropriate nerve at the distal limb and acquiring afferent volleys along the course of the nerve (peripherally at the nerve, on the dorsum of the neck and on the scalp). SSEPs were obtained prior to incision and baseline data were established. All SSEP and EMG (spontaneous and triggered) monitoring was performed by an intraoperative neurophysiologist board certified in neurophysiological intraoperative monitoring.

**TABLE 1. Muscles Used for EMG During Surgical Procedures Where Saphenous SSEP Changes Occurred**

Muscles Used for EMG
Vastus lateralis muscle (femoral nerve, L2–L4)
Vastus medialis muscle (femoral nerve, L2–L4)
Tibialis anterior muscle (sciatic nerve/deep peroneal nerve, L4–L5)
Gastrocnemius muscle (sciatic nerve/posterior tibial nerve, L5, S1–S2)
<i>EMG indicates electromyography; SSEP, somatosensory evoked potential.</i>

### Saphenous Nerve SSEP

Because of the relative depth of the saphenous nerve, this stimulus is delivered through 2 subdermal needle electrodes (anode and cathode). The stimulating electrodes are placed in the groove between the vastus medialis muscle and sartorius muscle in the medial distal thigh about 1 to 4 cm apart about 10 cm superior to the medial epicondyle of the knee (Figure 1). Bilateral stimulation was used with a focus on the side of access. Two hundred to 500 sweep trials are used to obtain



**Figure 1.** Electrode placement for saphenous SSEP stimulus. Stimulus is delivered in the groove between the VM and SAR. Block arrow denotes stimulus cathode (active); line arrow, stimulus anode (reference). SSEP indicates somatosensory evoked potential; VM, vastus medialis; SAR, sartorius.

the response and remove any ambient electrical interference. A repetition rate of 2.66 Hz and a stimulus intensity of 40 to 50 mA were used. Acquisition sites include a subdermal needle electrode placed at the dorsum of the neck (subcortical response) and subdermal needle electrodes placed on the scalp at the CPz location of the international 10-20 system (cortical response). SSEP acquisition sites are referenced to Fz of the international 10-20 system. Where adequate saphenous nerve SSEPs were obtained, the responses showed reproducible latencies in the mid-to-late 30-millisecond range. This is variable from patient to patient, taking into account body weight, limb length, anesthetic regimen, hemodynamics, and underlying medical causes. The subcortical responses were not well defined in most surgical procedures due to lack of neuromuscular blocking agents used for these specific procedures. The cortical response was stable and reproducible when obtained. An alarm criterion of 10% increase in latency and/or a 50%

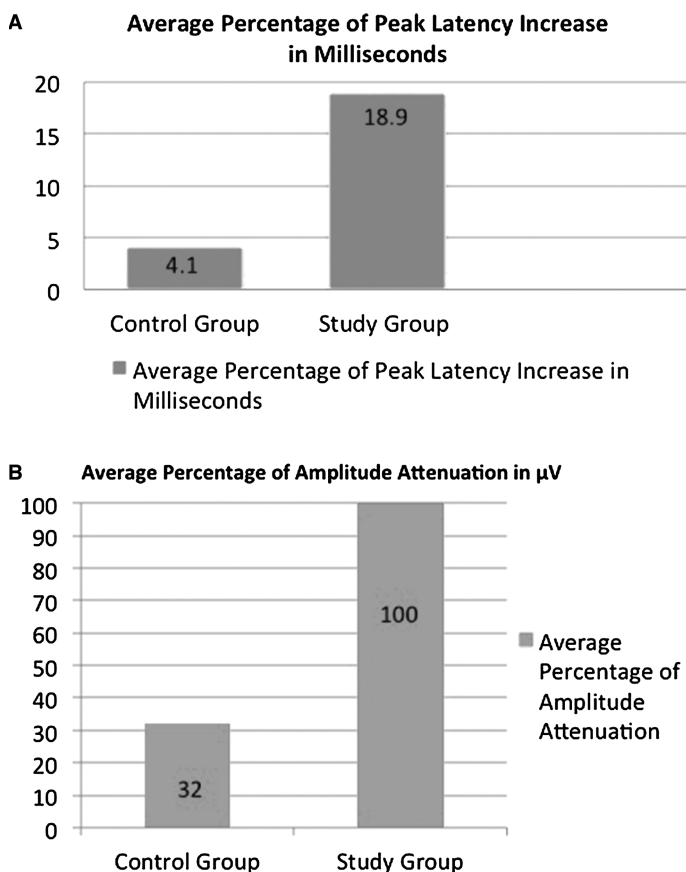
decrease in amplitude was used to relay changes to the surgeon for intervention.

### Neurophysiological Monitoring Technique

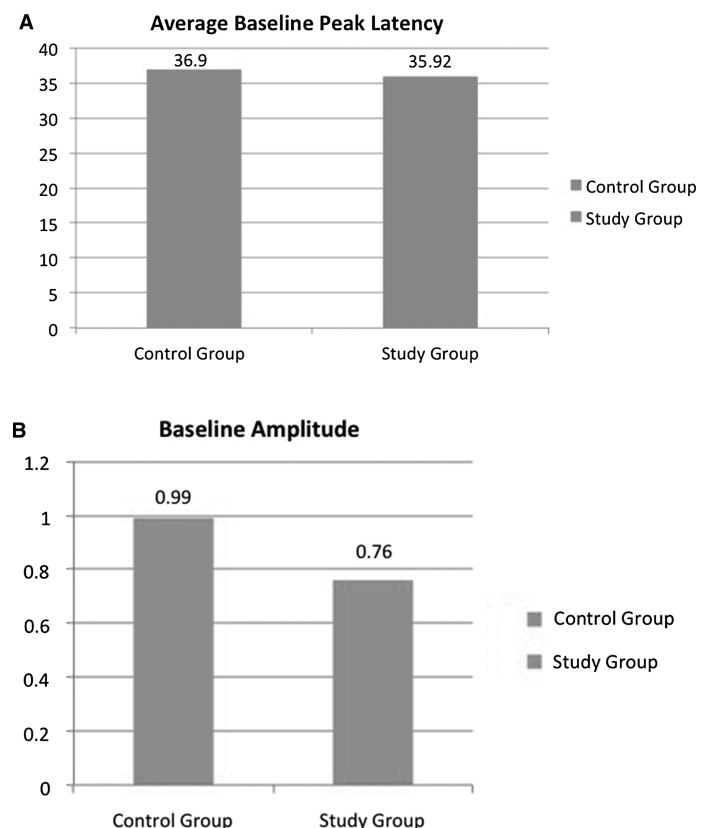
After baseline data were established from all nerves used for SSEPs prior to skin incision, s-EMG and t-EMG became the focus during initial dilator and retractor placement. This allowed the lumbar plexus to be adequately mapped and the proximity of the nerves to the surgical field be relayed to the surgeon. Once the retractors were placed and opened, the saphenous SSEP became the focused modality that was being continuously run until the retractors were removed. The maximum increase in latency and maximum decrease in amplitude while the retractor was in place was recorded. Upper extremity SSEPs were also run continuously to monitor for positional changes; however, deep peroneal and posterior tibial nerve SSEPs were run intermittently throughout the discectomy and interbody fusion.

### DATA ANALYSIS

Multiple patient and surgical variables influence the SSEP recordings including, anesthesia, hemodynamics, core temperature, limb length, and underlying comorbidities. Therefore,



**Figure 2. A**, This chart represents the average percentage of peak latency increases between the group with no perceived changes (control) and the group that showed intraoperative saphenous SSEP changes (study) when reviewing the L4–L5 level while the retractor is in place compared with baseline data. The control group exhibited an average increase in peak latency of 4.1%, whereas the study group exhibited an average peak latency increase of 18.9%. Peak latency is measured in milliseconds. **B**, This chart represents the average percentage of amplitude loss (measured in  $\mu\text{V}$ ) between the control group and the study group when reviewing the L4–L5 level while the retractor was in place compared with baseline data. The control group exhibited an average decrease in amplitude by 32%, whereas the study group exhibited an average decrease in amplitude of 100%. SSEP indicates somatosensory evoked potential.



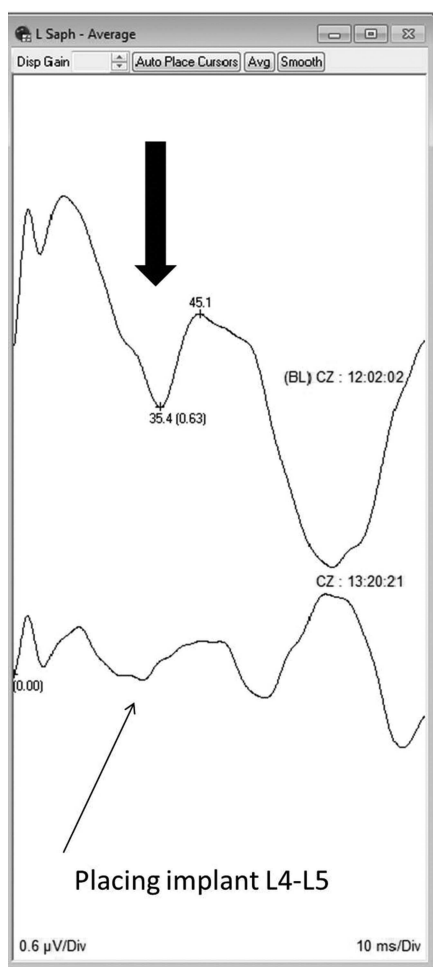
**Figure 3. A**, This chart represents the average for preincision baseline peak latency from the control and study groups. The average baseline peak latency is 36.9 milliseconds from the control group and 35.92 milliseconds from the study group. **B**, This chart represents the average preincision baseline amplitude from the control and study groups. The average preincision baseline amplitude is 0.99  $\mu\text{V}$  from the control group and 0.76  $\mu\text{V}$  from the study group.

there are no absolute numerical ranges that can represent this subset of patient's normal physiological parameters. The American Clinical Neurophysiology Society<sup>10</sup> (2009) discuss alarm criterion for intraoperative SSEP data as a 10% increase in latency and/or a 50% decrease in amplitude. The study group was defined as demonstrating peak latency increases greater than 10% and/or amplitude attenuation greater than 50%. The remainder of patients was considered the control group. All saphenous SSEP changes occurred while the retractor was in place at L4–L5. The investigators reviewed the saphenous SSEP recordings (amplitude and latencies) from preincision baseline through removal of retractor at L4–L5. The mean percentage for amplitude attenuation and latency increase during this time were calculated. These values were then compared between the control group (n = 36) and study group (n = 5) (Figure 2A, B). The mean average baseline data from the 2 groups were calculated as well (Figure 3A, B).

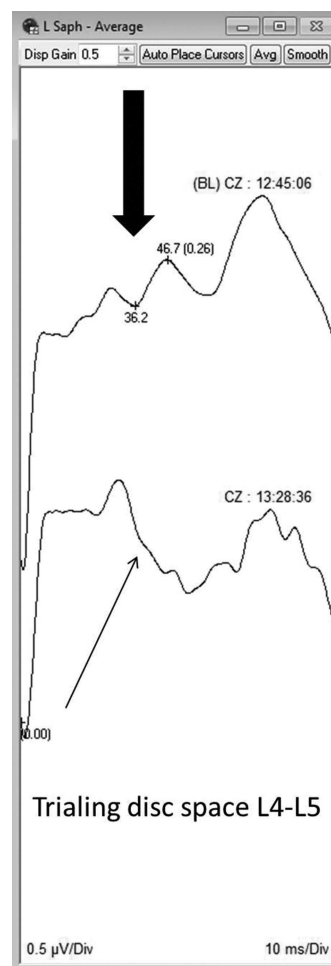
## RESULTS

Our case series consisted of a total of 46 patients. Five patients were excluded because of the inability to obtain baseline SSEP

data from the saphenous nerve either due to underlying medical causes, technical issues, or body habitus. The remaining study group consisted of 16 males and 25 females with 213 surgical levels averaging 31 minutes of surgical time per level. The average age for the cohort was 53 years. The mean height of the cohort was 67 in. and the mean weight was 83.9 kg. Five surgical procedures showed intraoperative changes of the saphenous SSEP. Saphenous SSEP changes were seen in 3 males and 2 females. All changes with the saphenous SSEP occurred after the retractor was placed and opened at the level of L4–L5 and were focal to the saphenous nerve only; all other SSEP recordings remained within baseline limits. It is also important to note that there was no s-EMG activity noted from any L4 innervated or femoral nerve innervated muscles when saphenous SSEP changes occurred. In patient 1, there was an attenuation of the SSEP on the approach side and the surgeon was alerted (Figure 4). Retractors were adjusted and return of the potentials was found. The patient woke up neurologically intact. In 4 other cases, changes in the SSEP data persisted and 3 of the patients woke up with postoperative deficits. Patient 2 woke up with generalized left lower



**Figure 4.** Loss of ipsilateral intraoperative saphenous SSEP during the placement of interbody arthrodesis at L4–L5. Block arrow denotes baseline SSEP recording; line arrow, SSEP change. SSEP indicates somatosensory evoked potential.



**Figure 5.** Loss of ipsilateral intraoperative saphenous SSEP during the trial for the interbody arthrodesis at L4–L5. Block arrow denotes baseline SSEP recording; line arrow, SSEP change. SSEP indicates somatosensory evoked potential.

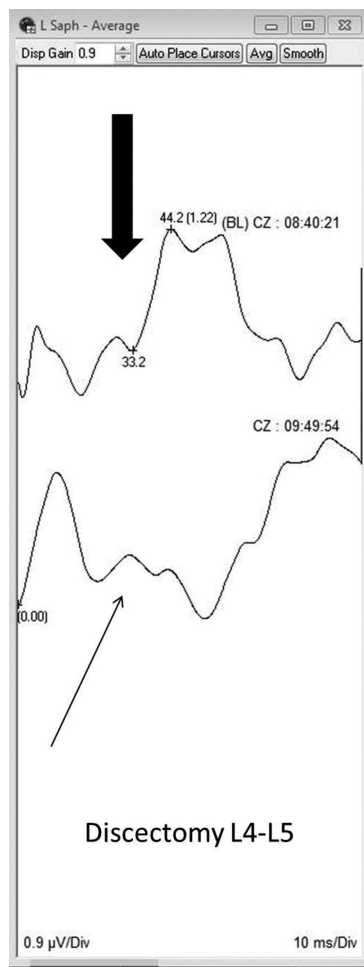
extremity paresthesia that resolved by his first office follow-up (Figure 5). However, at his second office visit, he had new complaints of generalized left lower extremity pain and paresthesia. Patient 3 woke up with complaints of numbness in the thigh (femoral nerve/saphenous nerve distribution), which persisted to his first and second office follow-ups (Figure 6). Patients 4 and 5 both awoke with sensory changes in their femoral distribution and both had femoral motor weakness at their first and second postoperative office visits (Figures 7, 8).

## DISCUSSION

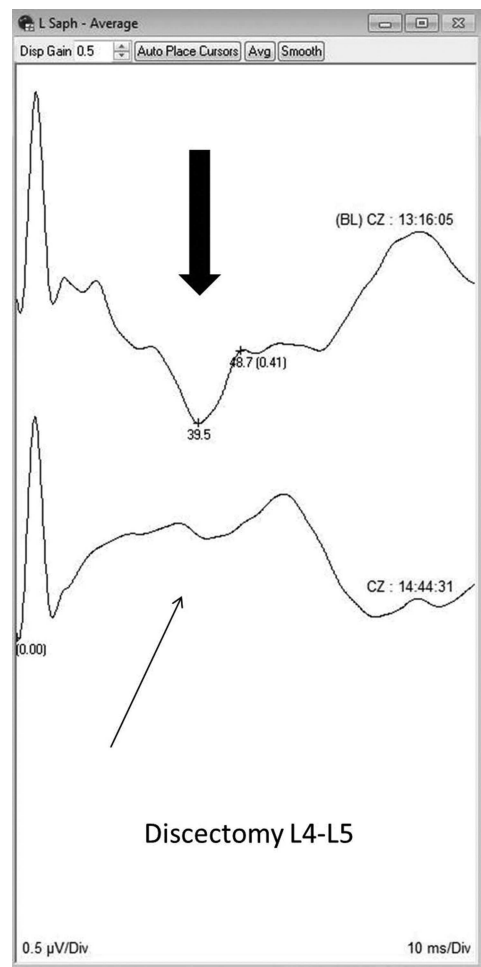
Various reports in the literature describe the use of intraoperative monitoring to safely expose the lumbar discs *via* the lateral transpoas approach; however, this is limited to EMG (spontaneous and triggered).<sup>1-5,7-9,11,12</sup> Nerve compression and/or ischemia are significant possible causes of nerve injuries in this approach.<sup>1,2,13,14</sup> EMG may not be sensitive for these injuries. Duncan *et al*,<sup>6</sup> were the first to report nerve root injury secondary to ischemia with no reciprocal EMG firing. Because of the nature of the continuous EMG monitoring technique, this type of injury may not be observed. To

improve the safety of this procedure, a more sensitive measure of the compression of the femoral nerve is needed. Loss of distal sensation may be the most sensitive measure of nerve pressure and ischemia. By monitoring the loss of sensation in the leg, prediction and prevention of femoral nerve injury may be possible. The saphenous branch is the distal sensory continuation of the femoral nerve. By monitoring the SSEP from this nerve, we should, in theory, be able to monitor the integrity of the femoral nerve as it travels through the psoas muscle.

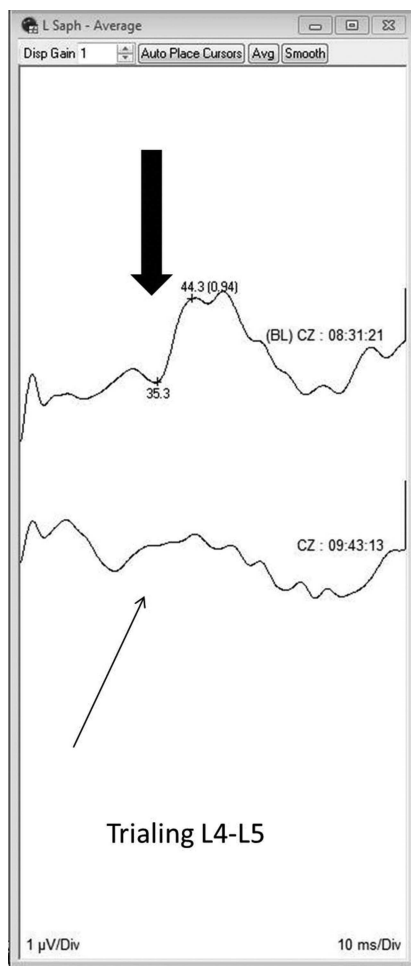
In this review of 41 lateral approaches to the lumbar spine using this technique, 100% of the femoral nerve injuries were detected using the saphenous nerve SSEP modality. In the 1 case where SSEP changes were detected and the patient woke up intact, the SSEPs returned to normal limits after the surgeon was notified and retractors were adjusted. However, in the remaining 4 cases where the SSEPs changed, 3 woke up with varying degrees of neurological deficit and 1 patient woke up with generalized symptoms. Using these data, the positive predictive value of this technique is 75%; the negative predictive value is 100%. Whereas, generalizing these data with this small cohort may not be appropriate at this time, a saphenous



**Figure 6.** Loss of ipsilateral intraoperative Saphenous SSEP during the discectomy at L4–L5. Block arrow indicates baseline SSEP recording; line arrow, SSEP change. SSEP indicates somatosensory evoked potential.



**Figure 7.** Significant morphology change with decreased amplitude and increases peak latency from ipsilateral saphenous SSEP during the discectomy at L4–L5. Block arrow denotes baseline SSEP recording; line arrow, SSEP change. SSEP indicates somatosensory evoked potential.



**Figure 8.** Loss of ipsilateral intraoperative saphenous SSEP during the trial for the interbody arthrodesis at L4–L5. Block arrow denotes baseline SSEP recording; line arrow, SSEP change. SSEP indicates somatosensory evoked potential.

SSEP that remains intact throughout the transpoas procedure should be reassuring to the surgeon. Further study is required to see if changing of surgical technique after receiving an SSEP alert can avoid a neurological injury. On the basis of multiple previous studies regarding intraoperative SSEP alerts, one would expect that adjusting the retractor and exposure may allow the SSEP to return to normal.<sup>15–23</sup>

The transpoas lateral interbody fusion is the only approach marketed to require neurophysiological monitoring.<sup>3,4,24</sup> s-EMG is only a reliable tool to assess whether the surgeon is irritating the nerve with direct mechanical trauma, whereas t-EMG informs the surgeon to the proximity of the nerves and nerve roots nearing the surgical field.<sup>5–8,12,24</sup> If the nerve becomes ischemic due to compression of the retractor blades, the s-EMG may not fire and remain electrically silent and the t-EMG specific for transpoas lateral interbody fusions will not indicate any change in neural function with regards to impending neurological sequelae.<sup>6,24</sup> SSEPs are typically used to monitor for gross spinal cord changes or injuries that occur because of patient positioning, as well as nerve root injuries that can occur during interbody arthrodesis.<sup>6,22,23,25–27</sup> If the

fully formed femoral nerve trunk becomes ischemic, prediction of impending neurological damage will not be assessed using current SSEP techniques.<sup>6,8</sup> To adequately perform this technique, a qualified neurophysiological monitoring clinician must be present to acquire and analyze the response of the saphenous nerve SSEP, as well as relay pertinent information to the operating surgeon.

## CONCLUSION

To our knowledge, this is the first report to describe specific neurophysiological monitoring for femoral nerve ischemia and/or compression injury associated with retractor placement during transpoas lateral interbody fusion procedures. Our findings suggest that saphenous nerve SSEP is a sensitive modality to predict impending femoral nerve injury. We also report that there was no s-EMG activity noted in our patients who suffered postoperative deficits indicating that EMG is not a sensitive modality to monitor for femoral nerve injury during lateral transpoas approaches. Adding saphenous nerve SSEPs to the neurophysiological monitoring paradigm for transpoas lateral access approaches at the L4–L5 levels may reduce the incidence of iatrogenic femoral nerve injury. If an intraoperative change in the saphenous SSEP is encountered, this may allow for a change of surgical technique (*e.g.*, retractor adjustment) or anesthetic management (*e.g.*, increasing the blood pressure). The presented initial data is promising; however, increasing numbers of patients in this series and/or review of a prospectively collected cohort will allow for better statistical methods, better definition of the sensitivity and specificity of this modality, and a better understanding of the efficacy of this alert in preventing injury.

## ➤ Key Points

- ❑ Femoral nerve injury is a potential complication after lateral lumbar interbody fusions.
- ❑ Femoral nerve injury may occur because of retractor compression.
- ❑ Saphenous nerve SSEPs may be a more sensitive modality to detect femoral nerve ischemia caused by compression compared with EMG.

## References

1. Pumberger M, Hughes AP, Huang RR, et al. Neurologic deficit following lateral lumbar interbody fusion. *Eur Spine J* 2012; 21:1192–9.
2. Lykissas MG, Aichmair A, Hughes AP, et al. Nerve injury after lateral lumbar interbody fusion: a review of 919 treated levels with identification of risk factors. *Spine J* 2013;13.
3. Rodgers WB, Gerber EJ, Patterson J. Intraoperative and early postoperative complications in extreme lateral interbody fusion: an analysis of 600 cases. *Spine* 2011;36:26–32.
4. Ozgur BM, Aryan HE, Pimenta L, et al. Extreme lateral interbody fusion (XLIF): a novel surgical technique for anterior lumbar interbody fusion. *Spine J* 2006;6:435–43.
5. Tohmeh AG, Rodgers WB, Peterson MD. Dynamically evoked, discrete-threshold electromyography in the extreme lateral interbody fusion approach. *J Neurosurg Spine* 2011;14:31–7.

6. Duncan JW, Bailey RA, Baena R. Intraoperative decrease in amplitude of somatosensory-evoked potentials of the lower extremities with interbody fusion cage placement during lumbar fusion surgery. *Spine (Phila Pa 1976)* 2012;37:E1290–5.
7. Gonzalez AA, Jeyanandarajan D, Hansen C, et al. Intraoperative neurophysiological monitoring during spine surgery: a review. *Neurosurg Focus* 2009;27:E6.
8. Davis T, Bae H, Mok J, et al. Lumbar plexus anatomy within the psoas muscle: implications for the transpsoas lateral approach to the L4–L5 disc. *J Bone Joint Surg* 2011;93:1482–7.
9. Houten JK, Alexandre LC, Nasser R, et al. Nerve injury during the transpsoas approach for lumbar fusion: report of 2 cases. *J Neurosurg Spine* 2011;15:280–4.
10. American Clinical Neurophysiology Society. *Guideline 11B: Recommended Standards for Intraoperative Monitoring of Somatosensory Evoked Potentials*. 2009. Retrieved from ACNS.org.
11. Sofianos DA, Briseño MR, Abrams J, et al. Complications of the lateral transpsoas approach for lumbar interbody arthrodesis: a case series and literature review. *Clin Orthop Relat Res* 2012;470:1621–32.
12. Bindal R, Ghosh S. Intraoperative electromyography monitoring in minimally invasive transforaminal lumbar interbody fusion. *J Neurosurg Spine* 2007;6:126–32.
13. Burnett MG, Zager EL. Pathophysiology of peripheral nerve injury: a brief review. *Neurosurg Focus* 2004;16:E1.
14. Sunderland S. A classification of peripheral nerve injuries producing loss of function. *Brain* 1951;74:491–51.
15. York DH, Chabot RJ, Gaines RW. Response variability of somatosensory evoked potentials during scoliosis surgery. *Spine (Phila Pa 1976)* 1987;12:864–76.
16. Machida M, Weinstein SL, Yamada T, et al. Dissociation of muscle action potentials and spinal somatosensory evoked potentials after ischemic damage of spinal cord. *Spine (Phila Pa 1976)* 1988;13:1119–24.
17. Bennett HL, Benson DR. Somatosensory evoked potentials for orthopaedic spine trauma. *J Orthop Trauma* 1989;3:11–8.
18. Manninen PH. Monitoring evoked potentials during spinal surgery in one institution. *Can J Anaesth* 1998;45:460–5.
19. Balzer JR, Rose RD, Welch WC, et al. Simultaneous somatosensory evoked potential and electromyographic recordings during lumbosacral decompression and instrumentation. *Neurosurgery* 1998;42:1318–24.
20. Gunnarsson T, Krassioukov AV, Sarjeant R, et al. Real-time continuous intraoperative electromyographic and somatosensory evoked potential recordings in spinal surgery: correlation of clinical and electrophysiologic findings in a prospective, consecutive series of 213 cases. *Spine* 2004;29:677–684.
21. Luk KD, Hu Y, Wong YW, et al. Evaluation of various evoked potential techniques for spinal cord monitoring during scoliosis surgery. *Spine (Phila Pa 1976)* 2001;26:1772–7.
22. Krassioukov AV, Sarjeant R, Arkia H, et al. Multimodality intraoperative monitoring during complex lumbosacral procedures: indications, techniques, and long term follow-up review of 61 consecutive cases. *J Neurosurg Spine* 2004;1:243–53.
23. Leung YL, Grevitt M, Henderson L, et al. Cord monitoring changes and segmental vessel ligation in the “at risk” cord during anterior spinal deformity surgery. *Spine (Phila Pa 1976)* 2005;30:1870.
24. Rodgers WB, Cox CS, Gerber EJ. Early complications of extreme lateral interbody fusion in the obese. *J Spinal Disord Tech* 2010;23:393–7.
25. Raynor BL, Bright JD, Lenke LG, et al. Significant change or loss of intraoperative monitoring data: a 25-year experience in 12,375 spinal surgeries. *Spine (Phila Pa 1976)* 2013;38:E101–8.
26. Chung I, Glow JA, Dimopoulos V, et al. Upper-limb somatosensory evoked potential monitoring in lumbosacral spine surgery: a prognostic marker for position-related ulnar nerve injury. *Spine J* 2009;9:287–95.
27. Schwartz DM, Drummond DS, Hahn M, et al. Prevention of positional brachial plexopathy during surgical correction of scoliosis. *J Spinal Disord* 2000;13:178–82.