

# Technical note: Resolution of spontaneous electromyographic discharge following disk-space distraction during lateral transpsoas interbody fusion

Michael Neil Woodall, MD\*, Basheer Shakir, MD, Adam Smitherman, MD,  
Haroon Choudhri, MD

*Department of Neurological Surgery, Georgia Regents University, Augusta, GA*

## Abstract

**Purpose:** The lateral transpsoas interbody fusion (LTIF) is an increasingly popular minimally invasive technique for lumbar interbody fusion. Although a posterior approach to the lumbar spine has traditionally been favored for the treatment of canal stenosis and neural foraminal stenosis, a growing body of evidence suggests that indirect decompression of the spinal canal and neural foramen can be achieved using a lateral transpsoas approach to the lumbar spine. We present 2 cases that may suggest a role for spontaneous electromyography (s-EMG) monitoring in assessing the adequacy of decompression during LTIF.

**Methods:** The 2 cases presented in this technical note illustrate resolution of s-EMG firing during LTIF, following distraction across the disk space. Removal of the distracting device produced the return of s-EMG firing. Both of these cases were operated at the L2-3 level.

**Results:** In the first case, s-EMG firing was noted in the bilateral tibialis anterior leads. Resolution of EMG firing may suggest indirect decompression of the canal via ligamentotaxis as the L5 root traverses the L2-3 disk space. In the second case, s-EMG firing was noted in the left abductor hallucis and resolved with distraction of the L2-3 disk space. Again, this may be explained by canal decompression via ligamentotaxis as the S1 root traverses the L2-3 disk space.

**Conclusion:** In both cases, distraction across the disk space resulted in resolution of s-EMG discharges—this correlated with an improvement in symptoms. These findings may suggest a role for s-EMG as a marker for adequacy of decompression in a select subset of patients undergoing LTIF. Further study is needed to determine if resolution of s-EMG is a useful measure of indirect decompression during LTIF. © 2013 ISASS – The International Society for the Advancement of Spine Surgery. Published by Elsevier Inc. All rights reserved.

**Keywords:** LTIF; LLIF; XLIF; DLIF; Indirect decompression; Transpsoas

The lateral transpsoas interbody fusion (LTIF) is an increasingly popular minimally invasive technique for lumbar interbody fusion. Early attempts at the lateral transpsoas approach were complicated with high rates of injury to the lumbar plexus, but an improved understanding of normal anatomical relationships as well as advances in neuromonitoring have increased the safety of this approach.<sup>1–5</sup> Although a posterior approach to the lumbar spine has traditionally been favored for the treatment of canal stenosis and neural foraminal stenosis, a growing body of evidence suggests that indirect decompression of the spinal canal and neural foramen

can be achieved using a lateral transpsoas approach to the lumbar spine.<sup>6,7</sup> We present 2 cases that may suggest a role for spontaneous electromyography (s-EMG) monitoring in assessing the adequacy of decompression during LTIF.

## Case 1

A 70-year-old white male with a previous L3-S1 posterior decompression and fusion presented with pain radiating into the bilateral lower extremities, worse on the left than the right. Magnetic resonance imaging revealed a disk bulge at L2-3 with associated canal stenosis. (Figs. 1 and 2). He was taken to the operating room for a lateral transpsoas approach to the L2-3 disk space with diskectomy and interbody cage placement.

At the outset of the procedure, baseline s-EMG discharges were recorded from the bilateral tibialis anterior electrodes (Fig. 3). Once the diskectomy had been completed and the

Portions of this work were presented as a podium presentation at the Georgia Neurosurgical Society Spring meeting, Amelia Island, Florida, May 27, 2012.

\* Corresponding author: Michael Neil Woodall, MD, Department of Neurological Surgery, Georgia Regents University, 1120 15th St, BI-3088, Augusta, GA 30912. Tel: +706 721 3071; fax: +706 721 8084.

E-mail address: [mwoodall@gru.edu](mailto:mwoodall@gru.edu)

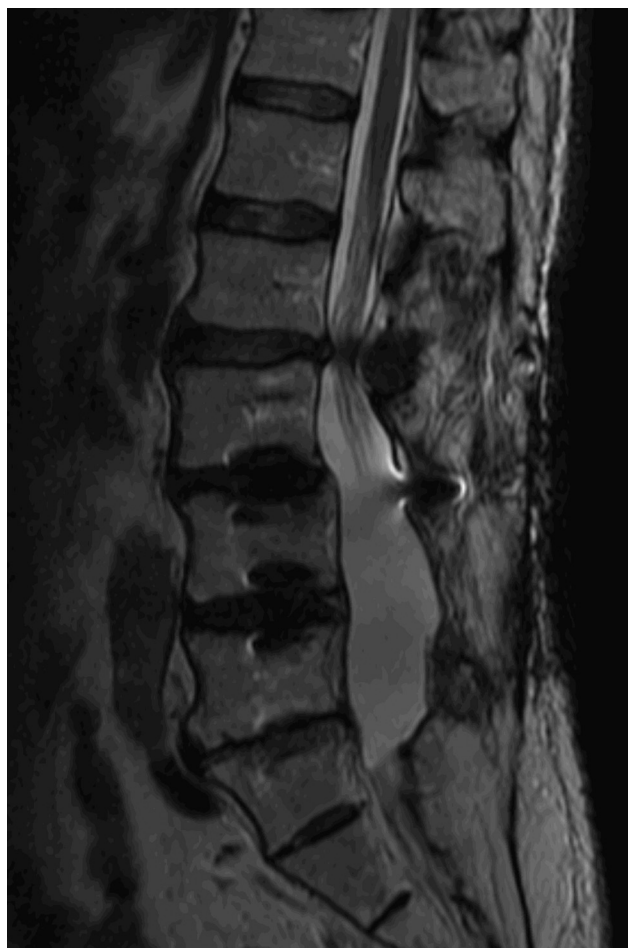

Fig. 1. Sagittal T2-weighted image of the lumbar spine.

endplates were prepared, a trial spacer was inserted into the disk space causing distraction across the disk space. At this time, s-EMG activity ceased. The trial was then removed, and the s-EMG activity returned. The interbody cage was then inserted into the disk space—again causing distraction

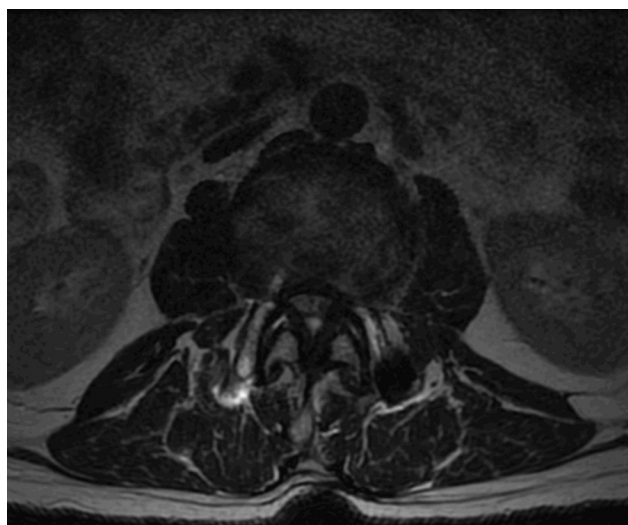


Fig. 2. Axial T2-weighted image of the lumbar spine.



Fig. 3. Spontaneous EMG activity in the tibialis anterior.

across the disk space—and the s-EMG discharges ceased (Fig. 4). The patient had immediate postoperative improvement in his radicular symptoms, although he had significant back pain attributed to presumed endplate injury during the procedure, which ultimately resolved.

### Case 2

A 67-year-old African American male with a previous L3-S1 posterior decompression and fusion presented with left thigh pain, left foot pain, and left hip flexor weakness. Workup revealed a herniated disk at L2-3 with canal stenosis and left neural foraminal stenosis. He was taken to the operating room for a lateral transposas approach to the L2-3 disk space with discectomy and interbody cage placement. At the start of the procedure, s-EMG discharges were noted from the left abductor hallucis electrode. As in Case 1, the spontaneous discharges ceased when the disk space was distracted by trial insertion. s-EMG discharges returned when the trial was removed, and then again ceased after cage placement. The patient experienced immediate improvement in his left-sided radicular pain. His quadriceps strength improved to baseline over the next several months.

### Discussion

Intraoperative neuromonitoring is an integral part of the LTIF procedure. Use of intraoperative EMG monitoring has decreased postoperative paresthesias secondary to lumbosacral plexus injury from 30% to 0.7%.<sup>1,2</sup> The monitoring modalities used during LTIF typically include somatosensory evoked potentials, s-EMG, and triggered EMG. During placement of the retractor system, the dilator is rotated while stimulating directionally. Response is typically monitored in the vastus medialis, tibialis anterior, biceps femoris, and medial gastrocnemius. Depending upon the amplitude required to illicit a response, the surgeon can estimate his proximity to the nerves of interest to avoid injury.<sup>5</sup>

Several recent studies suggest that indirect decompression is achieved with the LTIF procedure. Oliveira et al. radiographically measured an average 41.9% increase in disk height, 13.5% increase in foraminal height, 24.7% increase in foraminal area, and 33.1% increase in central canal diameter in patients after surgical treatment via the LTIF procedure.<sup>7</sup> Elowitz et al. documented a 54% increase in the anterior-posterior plane and a 48% increase in the




Fig. 4. Quiet EMG tracing in the tibialis anterior after cage placement.

medial-lateral plane of thecal sac dimensions for a calculated canal area increase of 143% after LTIF using magnetic resonance imaging. They concurrently measured statistically significant improvements in Oswestry disability index scale and treatment intensity scale measurements.<sup>8</sup>

Furthermore, using computed tomography scans, Kepler et al. reported a 35% increase in neural foraminal area. There was also a significant difference in preoperative and postoperative intervertebral disk height. Disk height was increased by 58% when measured in the midline anteriorly and by 70% when measured in the midline posteriorly. They also found statistically significant improvements in Oswestry disability index, Short Form-12 Mental Component Summary, and Physical Component Summary scores postoperatively.<sup>6</sup>

Resolution of s-EMG firing can be used to judge the adequacy of decompression during lumbar surgery. In a series of 120 cases of lumbar decompression via laminectomy, Beatty et al. noted baseline s-EMG firing in 18% of cases—which was usually associated with clinical weakness (64%). After decompression of the L4 root, baseline quadriceps firing ceased in 84% of patients. After decompression of the L5 root, baseline tibialis anterior firing ceased in 97% of cases; likewise decompression of the S1 nerve root alleviated gastrocnemius s-EMG firing in 100% of cases.<sup>9</sup>

The 2 cases presented in this manuscript illustrate resolution of s-EMG firing during LTIF, which may represent decompression of the affected nerve roots. Both of these cases were operated at the L2-3 level. In the first case, s-EMG firing was noted in the bilateral tibialis anterior leads. Resolution of EMG firing may be explained by indirect decompression of the canal via ligamentotaxis as the L5 root traverses the L2-3 disk space. In the second case, s-EMG firing was noted in the left abductor hallucis and resolved with distraction of the L2-3 disk space. Again, this may be explained by canal decompression via ligamentotaxis as the S1 root traverses the L2-3 disk space. In both cases, the patients experienced immediate postoperative improvement in their radicular symptoms.

### Clinical implications

Although s-EMG discharges may be because of positioning or surgical manipulation, there are several reasons to believe that s-EMG discharge in these 2 cases was related to pathological compression and resolved with indirect decompression. (1) s-EMG firing was present immediately following induction of anesthesia, before positioning. (2) s-EMG firing ceased with placement of the trial spacer and s-EMG firing returned when the trial spacer was removed in both cases. (3) s-EMG firing resolved with final placement of the interbody cage. Therefore, increased disk space height was associated with decreased s-EMG discharge.

EMG monitoring is employed routinely in the LTIF approach to monitor and protect the lumbosacral plexus during retractor placement. Unfortunately, only 18% of

patients with lumbar radiculopathy have s-EMG discharges at the time of surgery, usually patients who present with clinical weakness. In this subset of patients however, decompression of the involved root is associated with 84%, 97%, and 100% rates of s-EMG resolution for the L4, L5, and S1 roots respectively.<sup>9</sup>

Resolution of s-EMG firing could potentially serve as an indicator of adequacy of indirect decompression in a subset of patients undergoing LTIF.

### Conclusions

There is a growing body of evidence that indirect decompression of the spinal canal and neural foramina is achieved during LTIF. Previous authors have shown an association between resolution of s-EMG firing and adequate nerve root decompression in open lumbar surgery. We have observed cessation of s-EMG firing during LTIF associated with distraction across the disk space that has correlated with clinical improvement in radicular symptoms in these 2 patients.

EMG monitoring is a necessary tool to perform the LTIF procedure safely, to avoid injury to the lumbosacral plexus. There may be a subset of patients undergoing LTIF in whom resolution of s-EMG firing can be used as a marker for adequacy of indirect decompression intraoperatively. Further study is needed to correlate s-EMG cessation during LTIF with clinical and radiographic evidence of indirect decompression.

### References

1. Bergey DL, Villavicencio AT, Goldstein T, Regan JJ. Endoscopic lateral transpoas approach to the lumbar spine. *Spine (Phila Pa 1976)* 2004;29(15):1681–8.
2. Rodgers WB, Gerber EJ, Patterson J. Intraoperative and early postoperative complications in extreme lateral interbody fusion: An analysis of 600 cases. *Spine (Phila Pa 1976)* 2011;36(1):26–32.
3. Benglis DM, Vanni S, Levi AD. An anatomical study of the lumbosacral plexus as related to the minimally invasive transpoas approach to the lumbar spine. *J Neurosurg Spine* 2009;10(2):139–44.
4. Tohmeh AG, Rodgers WB, Peterson MD. Dynamically evoked, discrete-threshold electromyography in the extreme lateral interbody fusion approach. *J Neurosurg Spine* 2011;14(1):31–7.
5. Uribe JS, Vale FL, Dakwar E. Electromyographic monitoring and its anatomical implications in minimally invasive spine surgery. *Spine (Phila Pa 1976)* 2010;35(26 Suppl):S368–74.
6. Kepler CK, Sharma AK, Huang RC, et al. Indirect foraminal decompression after lateral transpoas interbody fusion. *J Neurosurg Spine* 2012;16(4):329–33.
7. Oliveira L, Marchi L, Coutinho E, Pimenta L. A radiographic assessment of the ability of the extreme lateral interbody fusion procedure to indirectly decompress the neural elements. *Spine (Phila Pa 1976)* 2010;35(26 Suppl):S331–7.
8. Elowitz EH, Yanni DS, Chwajol M, Starke RM, Perin NI. Evaluation of indirect decompression of the lumbar spinal canal following minimally invasive lateral transpoas interbody fusion: Radiographic and outcome analysis. *Minim Invasive Neurosurg* 2011;54(5–6):201–6.
9. Beatty RM, McGuire P, Moroney JM, Holladay FP. Continuous intraoperative electromyographic recording during spinal surgery. *J Neurosurg* 1995;82(3):401–5.