

# Video-Assisted Thoracoscopic Surgery Combined With a Tubular Retractor System for Minimally Invasive Thoracic Discectomy

Daniel S. Yann, MD\*

Cliff Connery, MD†

Noel I. Perin, MD, FRCS(E)‡

\*Department of Neurosurgery, University of California, Irvine Medical Center, Irvine, California; †St. Luke's, Roosevelt Medical Center, Department of Thoracic Surgery, New York, New York; and ‡Department of Neurosurgery, NYU Medical Center, New York, New York

#### Correspondence:

Noel I. Perin, MD, FRCS(E)  
Department of Neurosurgery,  
530 1st Avenue,  
Suite 8-S,  
New York, NY 10016.  
E-mail: noel.perin@nyumc.org

Received, April 20, 2009.

Accepted, October 1, 2010.

Copyright © 2011 by the  
Congress of Neurological Surgeons

**BACKGROUND:** Several approaches have been proposed for the treatment of thoracic disc herniations. Posterior approaches include transpedicular, costotransversectomy, and lateral extracavitary; anterior approaches include retropleural and transpleural thoracotomy and thoracoscopy.

**OBJECTIVE:** We present a novel minimally invasive approach to thoracic discectomies, combining thoracoscopy and a tubular retractor system. We discuss the utility and safety of this technique.

**METHODS:** The patient is placed in a lateral decubitus position, with a double-lumen endotracheal tube for single-lung ventilation. With use of thoracoscopic techniques, the disc space is identified; approximately 2 cm of the head and neck of the rib is removed to expose the pedicle of the lower vertebral body. The tubular retractor is deployed with continuous thoracoscopic visualization and a trough is created anterior to the canal by drilling the adjacent vertebral bodies straddling the disc space. The operative microscope is utilized to dissect the disc, pulling it anteriorly into the trough.

**RESULTS:** There were 5 patients in the past 9 months who were candidates for anterior thoracic discectomy. Disc herniations from T3-4 to T10-11 were treated without any significant complications. Patients were followed up clinically and radiographically.

**CONCLUSION:** Combining thoracoscopy with the tubular retractors allows continuous monitoring of the lung, aorta, and vena cava during the placement of the retractors. Additionally, use of the tubular retractors, as opposed to a complete thoracoscopic discectomy reduces the working distance and allows the use of the microscope with 3-dimensional visualization, thus enhancing the safety of this approach.

**KEY WORDS:** Extreme lateral, Microdiscectomy, Minimally invasive thoracic spine, Thoracoscopy, Video-assisted thoracoscopic surgery, XLIF-T

Neurosurgery 68[ONS Suppl 1]:ons138–ons143, 2011

DOI: 10.1227/NEU.0b013e318209348c

Thoracic disc herniations account for approximately 5 of every 1000 disc herniations encountered in clinical practice. Diagnosis of clinically significant thoracic disc herniations can be challenging if based solely on signs and symptoms. The advent of MR imaging has improved our ability to diagnose clinically significant thoracic disc herniations. Many different surgical approaches have been proposed over the years for the treatment of thoracic disc herniations.

**ABBREVIATION: VATS,** video-assisted thoracoscopic surgery

The approach can be influenced by many factors, including the consistency of the disc, the location in the canal, clinical presentation, and the level of the thoracic spine where the disc herniation occurs.<sup>1-3</sup> Many surgical approaches have been described. The posterolateral approaches include transpedicular, pedicle-sparing, costotransversectomy, and lateral extracavitary approaches. Anterior approaches to thoracic disc herniations include standard open thoracotomy, retropleural thoracotomy, and thoracoscopic discectomy. We present a novel minimally invasive approach to thoracic discectomy using a thoracoscopy-assisted approach by utilizing a tubular retractor system and the operating microscope (XLIF-T, NuVasive, San Diego, California).

## CLINICAL MATERIALS AND METHODS

We performed thoracoscopic-assisted XLIF-T thoracic microdiscectomy in 5 patients in the past 9 months. The average patient age was 58.8 (range, 44-80) and the operated levels spanned from T3-4 to T10-11. Patient symptomatology varied from intractable axial back pain with pain girdling around the chest wall, to bilateral lower extremity weakness with myelopathy and urinary incontinence. All patients had disc herniations that were midline and caused spinal cord compression. These patients were candidates for an anterior approach via standard thoracotomy or thoracoscopic discectomy. The levels of the disc herniations, patient characteristics, short-term outcomes, and surgical details are listed in Table 1.

### Surgical Technique

All patients with thoracic disc herniations had an MRI and CT scans in their preoperative workup. Patients also had a rib series, thoracic x-rays, and lumbar spine x-rays for intraoperative identification of the level. More recently, we have had these patients undergo preoperative CT-guided localization by the interventional radiology group. Twenty-four to 48 hours before surgery, these patients would have a metallic marker placed in the appropriate rib or pedicle under local anesthesia.

On the day of surgery, patients undergo general anesthesia with a double-lumen endotracheal tube to isolate the lung. Patients are positioned in the lateral decubitus position, with appropriate padding to all the pressure points. Cross table x-rays are obtained to localize the disc level to be treated, and the chest is routinely prepped and draped. All patients are monitored for motor and somatosensory evoked potentials throughout the procedure. The initial incision (10 mm) is made in line with the target disc noted on the cross table x-ray, just


posterior to the posterior axillary line. This incision serves as the working port. After an exploratory thoracoscopy, a second port is made rostral or caudal to the initial port in the anterior axillary line as a retraction port; if necessary, a third 7-mm port is placed as a suction port. The ribs are counted from within the chest cavity as well as with cross table x-rays to identify the appropriate disc level; this may be facilitated by the metallic marker placed preoperatively by interventional radiology. A "K" wire is then placed into the selected disc and a cross table antero-posterior x-ray of the thoracic spine is obtained. Once the disc has been identified definitively, the parietal pleura overlying the selected rib and the adjacent bodies is opened in an inverted "T" shape, using the harmonic scalpel (Ethicon Endo-Surgery, Hackensack, NJ). The radicular vessels overlying the bodies adjacent to the selected disc are isolated, bipolarized, clipped, and divided. The rib is then drilled about 2.5 cm from the head with use of a high-speed drill, the costovertebral attachment is disarticulated with a fine Cobb elevator, and this segment of rib is removed.

At this point, with the endoscope in place, we extend the working port at the posterior axillary line to about 3 cm. We then expose the inferior rib and remove an area of the superior aspect of the inferior rib to form a notch, facilitating placement of the working tube (Figure 1). Using the XLIF-T<sup>®</sup> tubular system (NuVasive, San Diego, CA), the tubular retractor of the appropriate length is placed under continuous endoscopic vision down to the selected disc space, and the retractor is fixed to the table-mounted holder (Figure 2). The medial blade is placed anteriorly to keep the lung out of the field. The tube is expanded rostrocaudally and anteriorly to afford exposure of the disc space and the adjacent vertebral bodies. If necessary, the fan retractor on the lung can be left attached to a table-mounted holder during the disc surgery. The operating microscope is brought into position to provide 3-dimensional visualization.

**TABLE 1. Chart of Patients Who Underwent Minimally Invasive Thoracic Microdiscectomy Using a Thoracoscopy-Assisted XLIF-T System<sup>a</sup>**

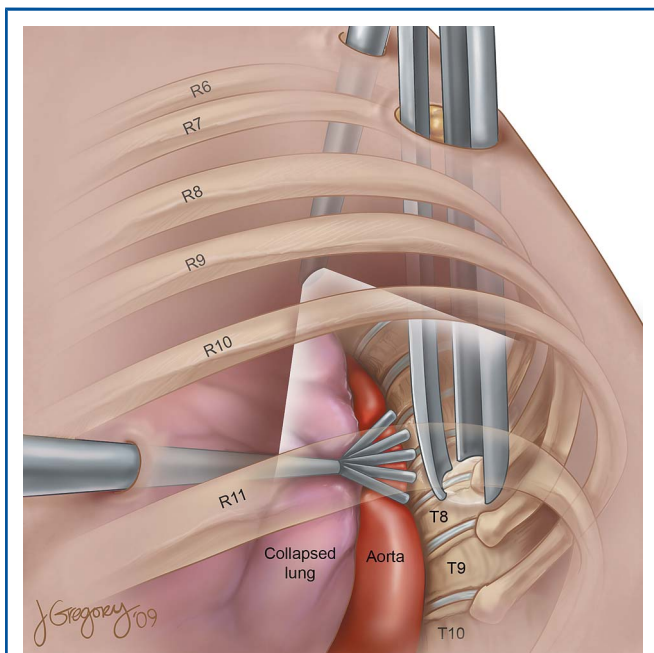
Patient	Age, y	Level	Calcified	Preoperative Localizer	Fusion	Short-term Outcome
1	62	T8/9	Yes	Yes	Noninstrumented anterior allograft	Preop burning axial thoracic pain; no girdling pains. Myelopathy with hip flexion weakness. Postop c/o severe intercostal neuralgia, intercostal nerve blocks afforded some relief (6 mo). Weakness improved. Good bone fusion 7 mo.
2	57	T10/11	Yes	Yes	Anterior allograft Posterior instrumentation	Preop progressive LE weakness and gait difficulty with ascending sensory loss, s/p prior laminectomy. T10-11. XLIF-T procedure with interbody iliac autograft combined with posterior stabilization/fusion. Postop regained normal strength. Resolution of axial pain. Good bone fusion noted interbody and postlateral at 8 mo.
3	51	T3/4	No	Yes	No	Preop midthoracic and scapular pain, crushing in nature. Sharp sternal pain. Postop dyesthesia in the T3 nerve distribution in anterior chest and right axillary region. Improvement after administration of Lyrica, back at work.
4	80	T9/10	Yes	Yes	Noninstrumented anterior allograft	Preop severe proximal leg weakness, in wheel chair, weakness improved, at 3 mo ambulating with walker. No pain, partial fusion interbody graft.
5	44	T7/8	No	No	No	Resolution of the girdling pains, some residual axial pain with activity, preop right leg weakness improved. Transient intercostal neuralgia

<sup>a</sup>C/o, complaint of; LE, lower extremity; preop, preoperative; postop, postoperative.



**FIGURE 1.** Intraoperative photograph of retractor system and thoracoscopic ports.

The removal of the head and neck of the rib allows the pedicle of the inferior vertebral body to be exposed. We then drill the posterior third of the vertebral bodies adjacent to the disc space and the superior half of the pedicle of the lower vertebral body straddling the disc space. Thus, a trough is created anterior to the canal extending from side to side and advancing toward the spinal canal. The drilling is continued until a thin cortical shell is left on the anterior wall of the canal with the herniated disc. Removing the superior half of the pedicle of the inferior vertebral body exposes the dura; this exposure is extended rostrocaudally. The



**FIGURE 2.** Artist's rendering of patient with placement of XLIF-T retractor system for thoracic microdiscectomy.

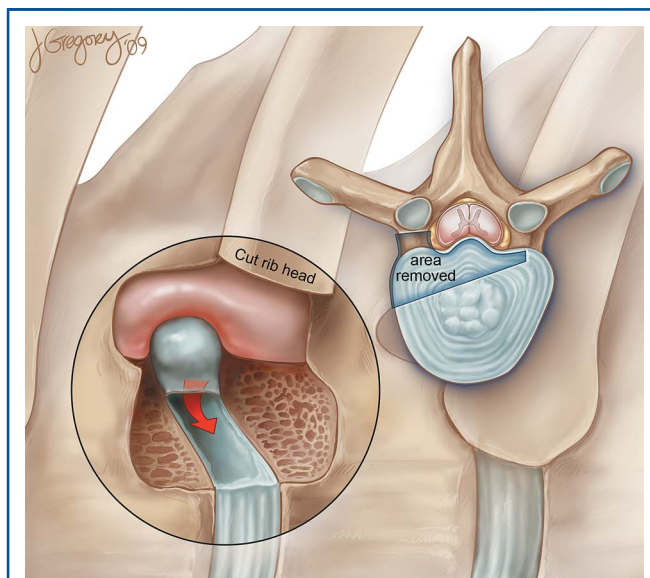
bony shell with the herniated disc pushing into the canal is now gently pulled back into the trough anterior to the canal, dissecting the disc away from the dura at the same time (Figure 3). Once the herniated disc is removed, a cross table x-ray is obtained to determine whether our dissection has extended to the opposite side of the canal.

Most patients do not have a fusion performed at the end of the discectomy. If it is estimated that a large segment of the vertebral bodies had been removed, an autograft rib or tricortical allograft is placed in the area of the vertebrectomy or in the remaining interspace anterior to the vertebrectomy defect. Finally, hemostasis is achieved, the tubular retractor is withdrawn, and a chest tube is placed via one of the posterior ports.

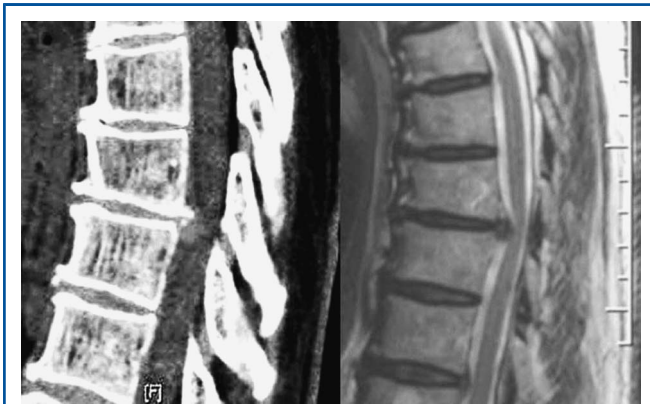**Illustrative Case**

A 62-year-old female (patient 1, Table 1) presented with a longstanding history of axial thoracic pain with radiation around her chest anteriorly. The patient was myelopathic with hyperreflexia, up-going plantar reflexes, and unsustained ankle clonus. The patient had proximal hip flexion weakness in the lower extremities. She denied any bladder or bowel dysfunction. MRI scans revealed a large, partially calcified, central disc herniation at T8/9 causing spinal cord compression (Figures 4 and 5).

With the patient in the left lateral decubitus position, the initial working port was placed at the posterior axillary line in the intercostal space that provided the most direct access to the T8/9 disc space. After an exploratory thoracoscopy, a second port was placed in the anterior axillary line at the 9th intercostal space. A fan retractor was positioned to retract the lung and the aorta away from the spine. A 5-mm suction port was placed in the 6th intercostal space in the posterior axillary line. After the T8/9 disc space had been identified, the parietal pleura over the 9th rib was opened and the radicular vessels on the bodies of T8 and T9 were isolated, clipped, and divided. The working port was then extended to 3 cm. The 9th rib was exposed at the working port and the bone was



**FIGURE 3.** Artist's rendering of the view through the tubular retractor showing the trough created by partial vertebrectomies and partial pediclectomy with disc herniation compressing the thecal sac.



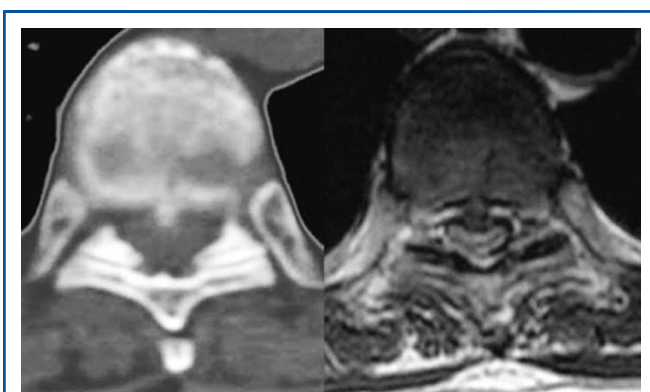
**FIGURE 4.** Preoperative CT and MRI sagittal views showing a calcified herniated disc with cord compression.

removed from the superior aspect of the rib to create space to allow placement of the tubular retractor. Approximately 2.5 cm of the head and neck of the 9th rib was removed to expose the pedicle of the T9 vertebral body. The retractor was placed down to the spine with continuous endoscopic visualization and docked straddling the disc space. Discectomy was carried out as described in the surgical technique section by use of the operative microscope.

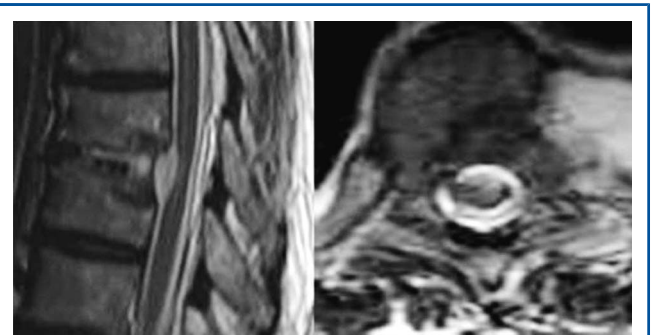In the short-term postoperative period, the patient’s pain and hip flexion weakness improved. Postoperative imaging revealed decompression of the spinal canal and thecal sac (Figure 6).

**RESULTS**

This technique of video-assisted thoracoscopy for placement of the tubular retractor system was utilized in the last 9 months for thoracic discectomy. Five patients had discectomies performed using the thoracoscopy-assisted XLIF-T® approach. All patients but one had a total removal of the disc herniation on postoperative MRI and CT scans. One patient (age, 80 years) who presented with progressive gait difficulty and a large calcified disc



**FIGURE 5.** Preoperative CT and MRI axial views showing a calcified herniated disc with cord compression.



**FIGURE 6.** Postoperative MRI sagittal and axial views demonstrating decompression of the canal with a tricortical bone graft in the disc space.

causing severe spinal cord compression had an adherent piece of calcified disc/posterior longitudinal ligament left on the dura after disconnecting the same from the rest of the disc. This patient did well postoperatively and was ambulating with a walker in the rehabilitation facility.

Overall, complications were minor, including one subcutaneous emphysema following chest tube removal and one deep venous thrombosis with a subclinical pulmonary embolism (while in rehabilitation). All patients had improvement or resolution of their preoperative symptoms (see Table 1). Three patients experienced intercostal neuralgia along the distribution of the thoracic ports. 2 were transient, and 1 patient had to be treated with intercostal nerve blocks and has had moderate resolution of the dysesthetic symptoms, although these symptoms still exist a year postsurgery.

We assessed the American Spinal Injury Association scores and Nurick scores for the 5 patients, pre- and postoperatively. Postoperative status was assessed at 1 year after surgery (Table 2).

**DISCUSSION**

Treatment of symptomatic thoracic disc herniations depends on clinical presentation (presence or absence of significant spinal cord compression), location of the disc herniation (central vs

**TABLE 2.** Pre- and Postoperative ASIA and Nurick Scores Assessed at a Minimum 1-Year Follow-up<sup>a</sup>

Patient	Age	Level	Calcified	Date of Operation	Nurick		ASIA	
					Preop	Postop	Preop	Postop
1	62	T8/9	Yes	02/10/09	1	0	D	E
2	57	T10/10	Yes	04/14/09	2	1	D	D
3	51	T3/4	No	01/07/09	0	0	E	E
4	80	T9/10	Yes	11/19/08	4	3	C	D
5	44	T7/8	No	10/01/08	0	0	E	E

<sup>a</sup>ASIA, American Spinal Injury Association; Preop, preoperative; Postop, postoperative.

paracentral), the consistency of the disc (presence of calcification), and surgeon familiarity with a selected technique. Paracentral and foraminal discs without significant spinal cord compression can be accessed from a posterior or posterolateral approach. Several posterior and posterolateral approaches have been described. The most popular are the transpedicular approach,<sup>4,5</sup> posterolateral pedicle-sparing approach,<sup>6</sup> costotransversectomy approach,<sup>7</sup> and the lateral extracavitary approach.<sup>8,9</sup> All of these approaches have their advantages and limitations for anterior decompression.

Large central and calcified disc herniations with significant spinal cord compression should be accessed from an anterior approach. The traditional anterior approach is via a thoracotomy.<sup>10</sup> The thoracotomy approach allows for a direct lateral view of the disc herniation and spinal cord and allows for a complete decompression of the cord. This technique allows for the disc herniation to be safely pulled away from the cord anteriorly, into a trough created by drilling of the vertebral bodies (Figure 3).

With the advent of video-assisted thoracoscopic surgery (VATS) in the early 1990s, thoracoscopy for thoracic discectomy gained popularity where an anterior approach was indicated.<sup>11-13</sup> Thoracoscopic discectomy is applicable in most instances for disc herniations arising from T2-3 through T12-L1.<sup>11-15</sup> Typically, 4 ports are used: an endoscopic port, working port, retraction port, and a suction port. Port locations can vary depending on the location of the disc herniation. The working port is placed in line with the disc space being accessed, along the posterior axillary line. Advantages of thoracoscopic discectomy include significant reduction of the postoperative thoracotomy pain and shoulder girdle dysfunction typically associated with an open thoracotomy. Disadvantages with a thoracoscopy are a steep learning curve, the necessity to work with long instruments, the lack of tactile feedback, and a 2-dimensional view of a three-dimensional surgical field.

We recently combined the thoracoscopic approach and the tubular retractor system XLIF-T<sup>®</sup> (NuVasive) to access thoracic disc herniations. Using the VATS approach, we are able to safely place the tubular retractors down to the spine under continuous thoracoscopic visualization. Other authors have described performing thoracic discectomy and vertebrectomy procedures using the tubular retractor system (NuVasive). However, this is done by blindly carrying the dilators along the rib, docking on the rib head, followed by placement of the working tube. Even with one-lung ventilation it is impossible to know whether the lung is being trapped with this blind placement. Additionally, our technique allows for the ability to take down any adhesions, retract the lung away from the operative site, and protect the aorta. We have sometimes left the fan retractor in place attached to a table-mounted holder to keep the lung, diaphragm, or aorta away from the field during the discectomy.

A minithoracotomy approach has been described by Mayer et al.<sup>16</sup> They used modified standard cervical retractors for use in the thoracic cavity. Using incisions 4 to 6 cm in length, discectomies were done with the microscope in some cases

and with an open thoracoscopic technique in others. They describe the technique for disc herniations between T5 to T10 only, and the approach in all cases was from the right side. Our technique is applicable from T3-4 through T11-12 from either side of the chest cavity, and we used a readily available retractor system (Nuvasive XLIF system) without modifications. The blades with shim attachments protected the lung and structures medially.

The advantage of using the tubular retractor is that we are able to use the operating microscope affording 3-dimensional visualization. This reduces distance to the target and gives us the ability to dissect the disc from the dura more safely and efficiently using operative magnification.

## CONCLUSION

The use of VATS-assisted placement of the tubular retractor system (XLIF-T<sup>®</sup> NuVasive) for thoracic discectomy is a safe and effective application of the serial tube dilation techniques utilized in other areas of the spine for performing minimally invasive surgery.

## Disclosure

The authors have no personal financial or institutional interest in any of the drugs, materials, or devices described in this article.

## REFERENCES

- Gille O, Soderlund C, Razafimahandri HJ, Mangione P, Vital JM. Analysis of hard thoracic herniated discs: review of 18 cases operated by thoracoscopy [published online ahead of print January 12, 2006]. *Eur Spine J*. 2006;15(5):537-542.
- Hott JS, Feiz-Erfan I, Kenny K, Dickman CA. Surgical management of giant herniated thoracic discs: analysis of 20 cases. *J Neurosurg Spine*. 2005;3(3):191-197.
- Sheikh H, Samartzis D, Perez-Cruet MJ. Techniques for the operative management of thoracic disc herniation: minimally invasive thoracic microdiscectomy. *Orthop Clin North Am*. 2007;38(3):351-361.
- Chi JH, Dhall SS, Kanter AS, Mummaneni PV. The Mini-Open transpedicular thoracic discectomy: surgical technique and assessment. *Neurosurg Focus*. 2008;25(2):E5.
- Patterson RH Jr, Arbit E. A surgical approach through the pedicle to protruded thoracic discs. *J Neurosurg*. 1978;48(5):768-772.
- Stillerman CB, Chen TC, Day JD, Couldwell WT, Weiss MH. The transfacet pedicle-sparing approach for thoracic disc removal: cadaveric morphometric analysis and preliminary clinical experience. *J Neurosurg*. 1995;83(6):971-976.
- Hulme A. The surgical approach to thoracic intervertebral disc protrusions. *J Neurol Neurosurg Psychiatry*. 1960;23:133-137.
- Larson SJ, Holst RA, Hemmy DC, Sances A Jr. Lateral extracavitary approach to traumatic lesions of the thoracic and lumbar spine. *J Neurosurg*. 1976;45(6):628-637.
- Maiman DJ, Larson SJ, Luck E, El-Ghatit A. Lateral extracavitary approach to the spine for thoracic disc herniation: report of 23 cases. *Neurosurgery*. 1984;14(2):178-182.
- Ransohoff J, Spencer F, Siew F, Gage L Jr. Transthoracic removal of thoracic disc. report of three cases. *J Neurosurg*. 1969;31(4):459-461.
- Anand N, Regan JJ. Video-assisted thoracoscopic surgery for thoracic disc disease: Classification and outcome study of 100 consecutive cases with a 2-year minimum follow-up period. *Spine*. 2002;27(8):871-879.
- Burke TG, Caputy AJ. Treatment of thoracic disc herniation: evolution toward the minimally invasive thoracoscopic technique. *Neurosurg Focus*. 2000;9(4):e9.
- Oskouian RJ, Johnson JP. Endoscopic thoracic microdiscectomy. *J Neurosurg Spine*. 2005;3(6):459-464.
- Bartels RH, Peul WC. Mini-thoracotomy or thoracoscopic treatment for medially located thoracic herniated disc? *Spine*. 2007;32(20):E581-E584.

15. Perez-Cruet MJ, Kim BS, Sandhu F, Samartzis D, Fessler RG. Thoracic micro-endoscopic discectomy. *J Neurosurg Spine*. 2004;1(1):58-63.
16. Mayer HM. Microsurgical anterior approach to T5-T10 (Mini-TTA). In: *Minimally invasive spine surgery*. Berlin, New York: Springer; 2005:129-137.
2. Mummaneni PV, Sasso RC: Minimally invasive, endoscopic, internal thoracoplasty for the treatment of scoliotic rib hump deformity: technical note. *Neurosurgery*. 2005;56:E444; discussion E444.

## COMMENTS

**W**e have removed thoracic disc herniations using a posterior minimally invasive transpedicular approach.<sup>1</sup> However, in cases of calcified, large, central disc herniations with spinal cord compression, resection from an anterior/lateral approach is preferred for visualization and for surgical access to the lesion. The authors report their experience with a minimally invasive lateral approach for such lesions. Their technique combines video-assisted thoracoscopic surgery (VATS) with the tubular retractor system commonly used for lateral lumbar minimally invasive approaches. The feasibility of this approach is nicely demonstrated in this article. It should be noted that VATS typically provides a 2-dimensional view on a televised monitor.<sup>2</sup> This is a disadvantage of thoracoscopy. Microscopic visualization through a laterally placed expandable tubular retractor is an alternative to provide 3-dimensional views. However, the depth of the surgical field sometimes precludes the use of the microscope. The authors are commended for providing details of their technique in this well written report.

**Jau-Ching Wu**  
*Taipei, Taiwan*

**Praveen V. Mummaneni**  
*San Francisco, California*

---

1. Chi JH, Dhall SS, Kanter AS, Mummaneni PV. The Mini-Open transpedicular thoracic discectomy: surgical technique and assessment. *Neurosurg Focus*. 2008;25:E5.

**T**he authors present a modification of thoracoscopic and open MIS surgical techniques for thoracic discectomy which takes advantage of the strengths of both techniques and compensates for some of the drawbacks of the individual techniques as well. The safety of the MIS technique is enhanced by using the thoracoscope to prepare the docking site for the tubular retractor, and some of the technical difficulties associated with the thoracoscopic technique (long working distance, 2D view) are ameliorated through the use of the MIS retractor. Creative application of existent technology to challenging surgical cases should be encouraged.

**Daniel K. Resnick**  
*Madison, Wisconsin*

**T**he authors describe 5 patients who had thoracic disc herniations that were treated by the combination of VATS and a tubular retractor system. They found these methods to be safe and effective.

The advantage, of course, is that the operation is minimally invasive while 3-dimensional visualization of the surgery site is available. The combination of these 2 methods, that is, the VATS and tubular retractor system, makes good sense, and the authors obtained excellent results. It will be interesting to know if long-term follow-up will confirm their experience.

**Volker K. H. Sonntag**  
*Phoenix, Arizona*